

## Histopathological study of experimental tooth movement in a rat model of type II diabetes mellitus

Hiroko Matsushita<sup>1</sup>, Kazuya Tominaga<sup>2</sup>, Akio Tanaka<sup>2</sup> and Naoyuki Matsumoto<sup>3</sup>

<sup>1</sup>Graduate School of Dentistry (Orthodontics), <sup>2</sup>Department of Oral Pathology and <sup>3</sup>Department of Orthodontics, Osaka Dental University, 8-1 Kuzuhahanazono-cho, Hirakata-shi, Osaka 573-1121, Japan

**Although it is thought that orthodontic treatment should be avoided in patients with diabetes mellitus, as the number of these patients increases, treatment may become necessary for some of them. We experimentally moved the teeth using the Waldo method in Goto-Kakizaki (GK) rats, an animal model of type II diabetes. On days 1, 3, 5 and 7 after initiation of tooth movement, we extracted three upper molars and the surrounding periodontal tissue *en bloc*, and measured the movement distance between the first (M1) and second (M2) molars. We also measured the distance between the dental crowns of the three teeth from the mesial of M1 to the distal of the third molar (M3). Afterward we made histopathologic observations.**

**Although measurements of tooth movement and inter-crown distance from M1 to M3 showed large values on the first day after initiation of the procedure in the control group, these measurements subsequently did not change. Histopathologically, there was dilation of the periodontal ligament capillaries on the tension side on post-procedure day 1 in both the control and experimental groups. On the pressure side, marked capillary dilation was seen on post-procedure day 5 in the controls and post-procedure day 3 in the experimental group. From post-procedure day 3 the course of the collagen fibers was disrupted in the experimental group and the stainability with silver impregnation staining increased compared with the controls. Thus, in the diabetic rats there was decreased metabolic function, blood supply, and ability to form multinucleated giant cells, and the structure of collagen fibers in the connective tissue was changed. The above suggests that time is required for tooth movement in diabetes and that there is a possibility of marked breakdown of periodontal tissue. (J Osaka Dent Univ 2016 ; 50 : 13-21)**

**Key words : Diabetes mellitus ; Orthodontics ; Pathological histology**

### INTRODUCTION

It is generally thought that orthodontic treatment should be avoided in patients with diabetes mellitus.<sup>1-3</sup> However, the number of diabetes patients in Japan is increasing<sup>4</sup> and there are circumstances when orthodontic treatment needs to be done. According to the 2012 National Health and Nutrition Survey, about 9.5 million people in Japan had a National Glycohemoglobin Standardization Program (NGSP) HbA1c level of 6.5%, an indicator of diabetes, and 11.0 million people had levels of 6.0% to less than 6.5%, indicating pre-diabetes. Thus, a total of 20.5 million people, or about

16% of the Japanese population, have diabetes or pre-diabetes.<sup>5</sup> Juvenile diabetes has also been increasing in recent years,<sup>3</sup> with a corresponding increase in the number of these children needing orthodontic treatment. However, the phenomena that will occur when orthodontic treatment is actually performed on people with diabetes are not understood at all. Therefore, elucidation of what may occur histopathologically should be of benefit in responding to the needs of these patients.

Goto-Kakizaki (GK) rats are an animal model of diabetes<sup>6</sup> that was developed from Wistar rats.<sup>1,7</sup> GK rats are non-obese rats in which a hyperglycemic condi-

tion is maintained.<sup>8</sup> Concomitant conditions including peripheral neuropathy,<sup>4</sup> mild nephropathy,<sup>9,10</sup> and microangiopathy<sup>11-13</sup> are also seen in these animals. Thus, they are a model that closely resembles type II diabetes, and may be considered very useful for the elucidation of the origin of the disease and the development of treatments. The mean blood sugar level of the GK rats used in this study was 145 mg/dL (data not shown), which is hyperglycemic compared with the level of  $110 \pm 1$  mg/dL that is said to be normal in Wistar rats.<sup>14</sup> In an extensive search of the literature we found no reported experiments using the Waldo method<sup>15-17</sup> for GK rats. To show the changes in periodontal tissue accompanying tooth movement in a diabetic state, we moved teeth experimentally and made histopathological observations of the condition of the periodontal tissue using this animal model of diabetes.

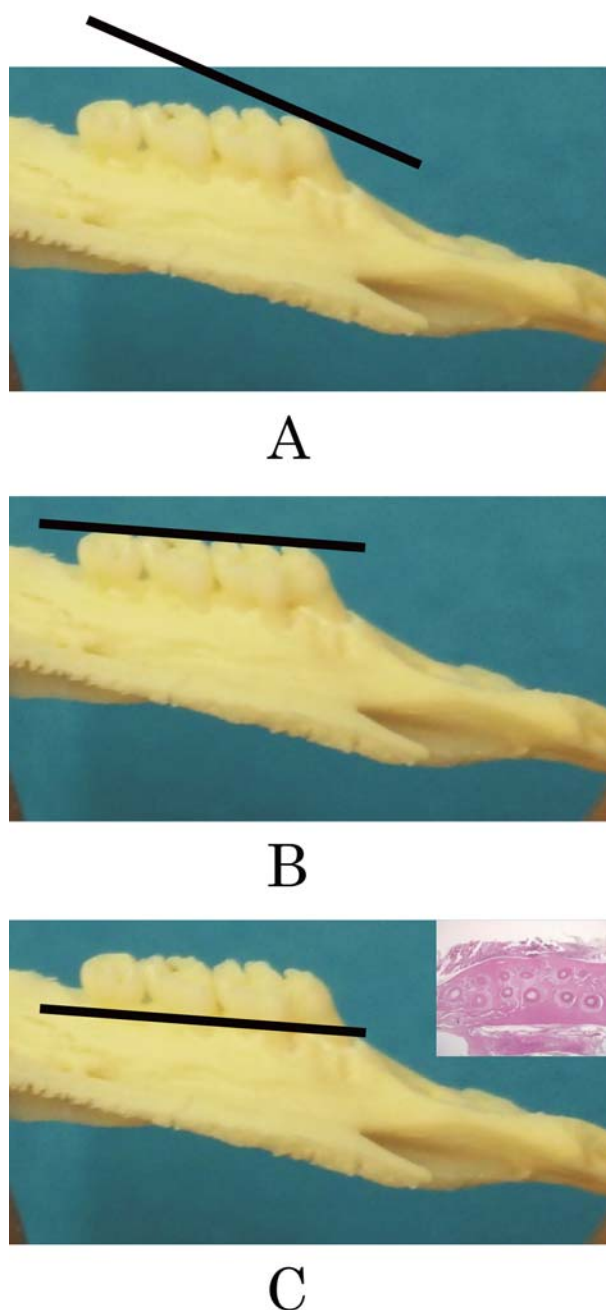
## MATERIALS AND METHODS

### Animals

Twenty, 8-week-old male GK rats<sup>3</sup> (experimental group; Shimizu Laboratory Supplies, Kyoto, Japan) and twenty, 8-week-old male Wistar rats (control group; Shimizu Laboratory Supplies) were used in the experiment.

### Experimental protocol

The Waldo method<sup>15-17</sup> was used for tooth movement. Elastic rubber bands (Unitek, Monrovia, CA, USA) were placed between the maxillary right M1 and M2 in the experimental and control groups,<sup>18,19</sup> imparting a tipping movement on the maxillary molars. The rubber bands were not placed in the left maxilla in order to compare the two groups. The rats were euthanized on days 1, 3, 5 and 7 after initiation of the procedure and perfusion fixed with 10% neutral buffered formalin solution, after which maxillary tissue, including the three upper molars, was collected. The movement distance between M1 and M2 of the collected tissue was measured by inserting a thickness gauge (Trusco Nakayama, Tokyo, Japan). The inter-crown distance between the three molars, from the mesial of M1 to the distal of M3, was measured with calipers. Afterward, demineralization<sup>20</sup> and paraffin embedding following

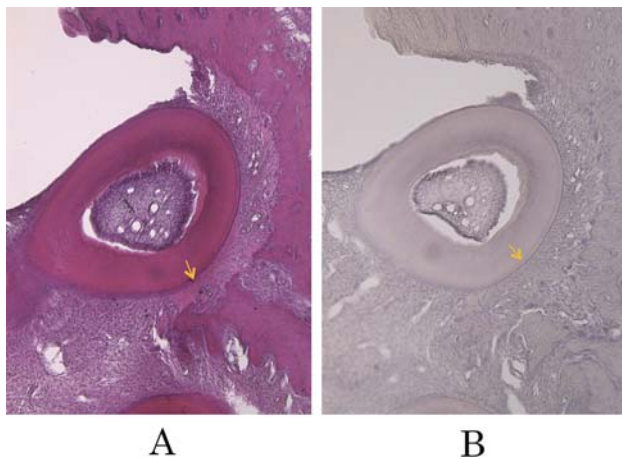


**Fig. 1** Trimming observation sites of rat maxillary specimens. The proximal side is to the right, with the first molar (M1), second molar (M2), and third molar (M3) toward the left. (A) Facing of the mesial cusp of M1, (B) Facing of all cusps from M1 to M3, (C) Observation surface from the crowns to the roots of M1, M2 and M3, which is the observation surface when the roots of the teeth are separated from the three crowns. The inserts are histopathological images of the root separation areas of the three molars. The black lines show the preparation surfaces of the sections.

conventional methods were done on day 1 using the same formalin solution, and on day 1 after immersion fixation with K-CX. The protocol for animal experiments was approved by the Animal Research Committee of Osaka Dental University (13-03007, 14-02021).

### Sectioning and staining

Consecutive sections with a thickness of 5  $\mu\text{m}$  were prepared from paraffin embedded blocks. The sections were stained with hematoxylin-eosin (HE), silver impregnation, and hematoxylin (H). The observation sites were horizontal sections so that the bifurcation area of the dental roots of all three molars could be seen. That is, the mesial cusp of M1 was trimmed (Fig. 1 A) and the orientations of the observation planes were matched so that all cusps from M1 to M3 were exposed (Fig. 1 B). The area where the roots of all three molars separate, from the crowns of M1, M2 and M3 to the roots (Fig. 1 C), was taken as the observation plane. As it was easier to discern multinucleated cells in specimens with H staining (Fig. 2 B) than in those with HE staining (Fig. 2 A), the number of multinucleated cells present in the M2 periodontal ligament of the observation sections were counted using H stained specimens.



**Fig. 2** Comparison of HE stain (A) and H stain (B) of the mesiobuccal root of the second molar on the third day of rubber band attachment in a Wistar rat (Original magnification  $\times 33$ ). Pressure side (yellow arrow).

## RESULTS

### Tooth movement measured with a thickness gauge

In the Wistar rat control group, the distance between M1 and M2 opened considerably on post-procedural day 1, after which it remained nearly unchanged. In the GK rat experimental group, this distance increased with each day (Fig. 3).

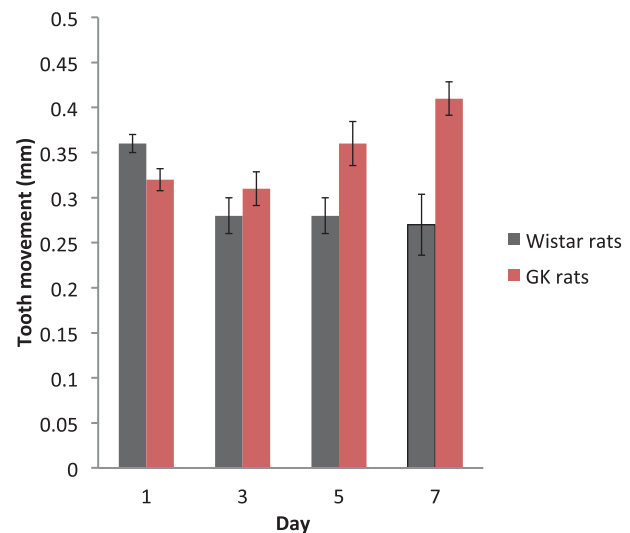
### Inter-crown distance from the medial of M1 to the distal of M3

The inter-crown distance in the group without rubber bands, which was also compared for both the Wistar and GK rats, was about  $6.7 \pm 0.07$  mm, with no significant difference between them. When rubber bands were attached in the Wistar rats, the inter-crown distance became larger after one day and subsequently shortened and stabilized at about  $7.0 \pm 0.1$  mm. When rubber bands were attached in the GK rats, the inter-crown distance was stable at about 6.9 mm throughout the experiment (Fig. 4).

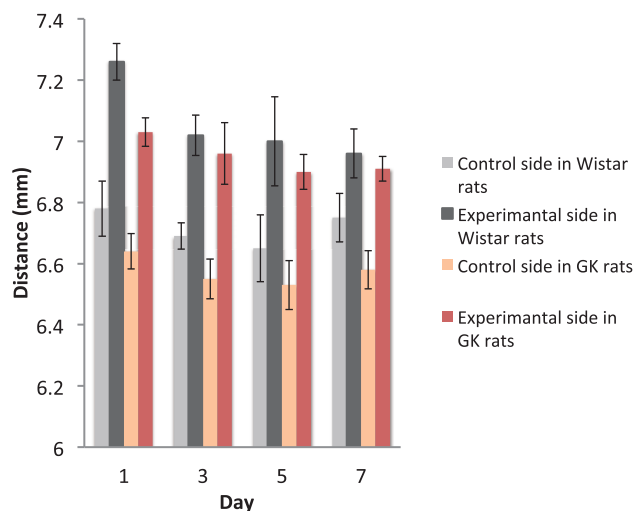
### Histopathological observations

#### *HE staining findings with attachment of elastic rubber bands in the Wistar rats (controls)*

On post-procedure day 1, the width of the periodontal ligament thickened on the tension side and narrowed



**Fig. 3** Tooth movement.



**Fig. 4** Distance from the mesial of M1 to the distal of M3.

on the pressure side (Figs. 5 A and B). Dilation of the capillaries was seen in the periodontal ligament on the tension side (Fig. 5 B). On post-procedural day 3, the dilation of the capillaries seen in the periodontal ligament was also observed on the pressure side (Figs. 5 D and E). Multiple Howship's lacunae and multinucleated cells appeared on the bone surface corresponding to the alveolar cortical plate on the pressure side (Figs. 2, 5 D and 5 E). Periodontal pockets formed between M1 and M2 (Figs. 5 D and E) and there was conspicuous inflammatory cell invasion in the connective tissue (Fig. 5 E).

On day 5, resorption lacunae were seen on the root surface on the pressure side (Figs. 5 G and H), and much dilation of the capillaries similar to that found in the periodontal ligament was seen on the pressure side (Figs. 5 G and H). The periodontal pockets formed between M1 and M2 spread over a wide area, exposing parts of the root (Fig. 5 G). On day 7, dilation of the capillaries was seen in sites with a strong inflammatory reaction on the pressure side and around the periodontal pockets (Figs. 5 J and K), parts of the root were exposed (Figs. 5 J and K), and the resorption lacunae seen on the root surface on the pressure side increased (Fig. 5 K).

#### *Silver impregnation staining findings with attachment of rubbers bands in the Wistar rats (controls)*

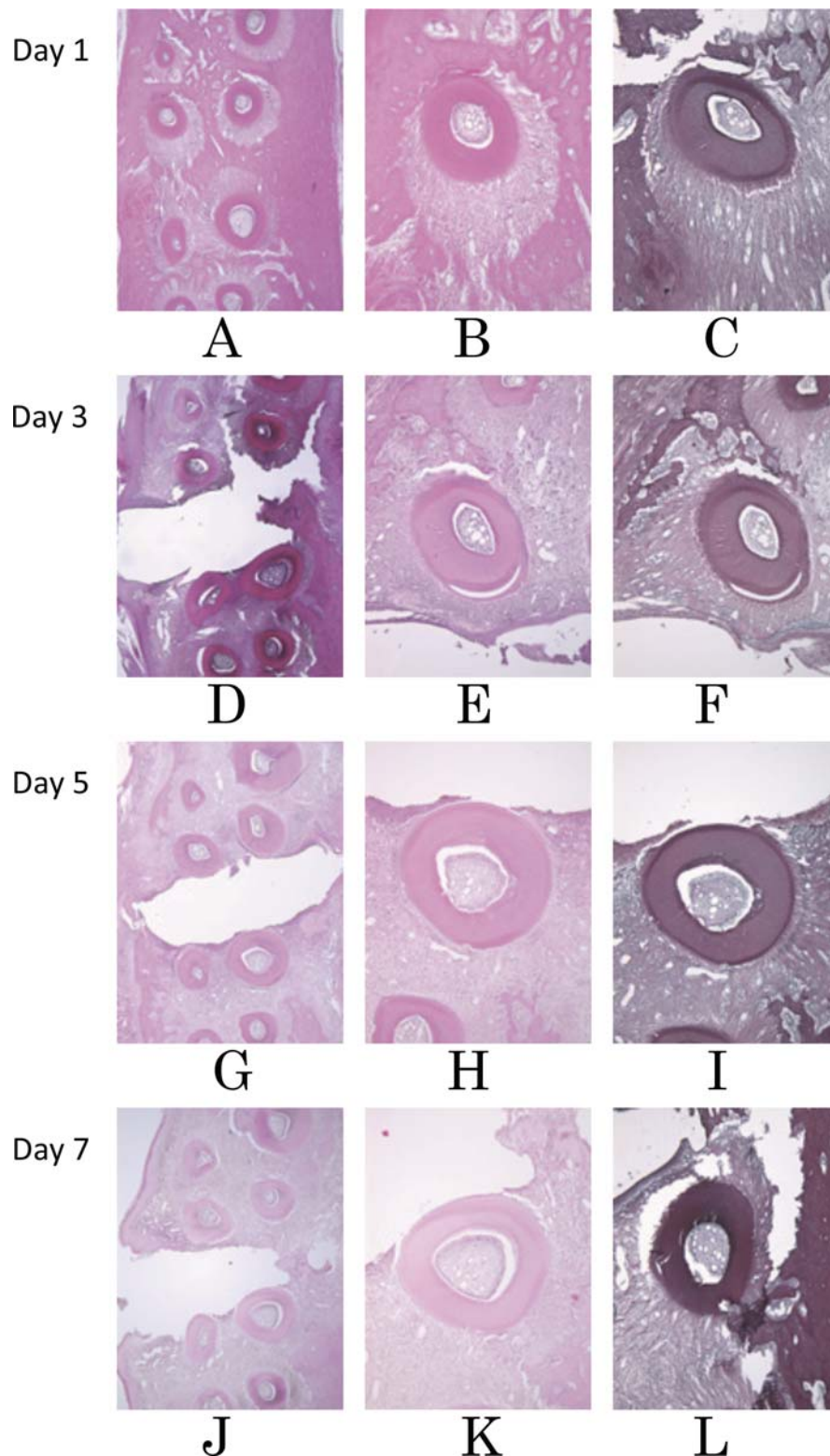
On post-procedural day 1, the collagen fibers of the periodontal ligament were taut on the tension side and relaxed on the pressure side, and dilated capillaries were observed on the tension side (Fig. 5 C). On day 3 periodontal pockets had formed (Fig. 5 F) and the appearance of tension in the collagen fibers on the tension side had disappeared and a relaxation of tension had appeared on the pressure side (Fig. 5 F). On day 5, reticular fibers were seen in the connective tissue as a result of the extensive periodontal pockets on the pressure side (Fig. 5 I). On day 7, mixed collagen and reticular fibers seemed to be entering the dilated capillaries in connective tissue around the periodontal pockets with a strong inflammatory response (Fig. 5 L).

#### *HE staining findings with attachment of elastic rubber bands in the GK rats (experimental group)*

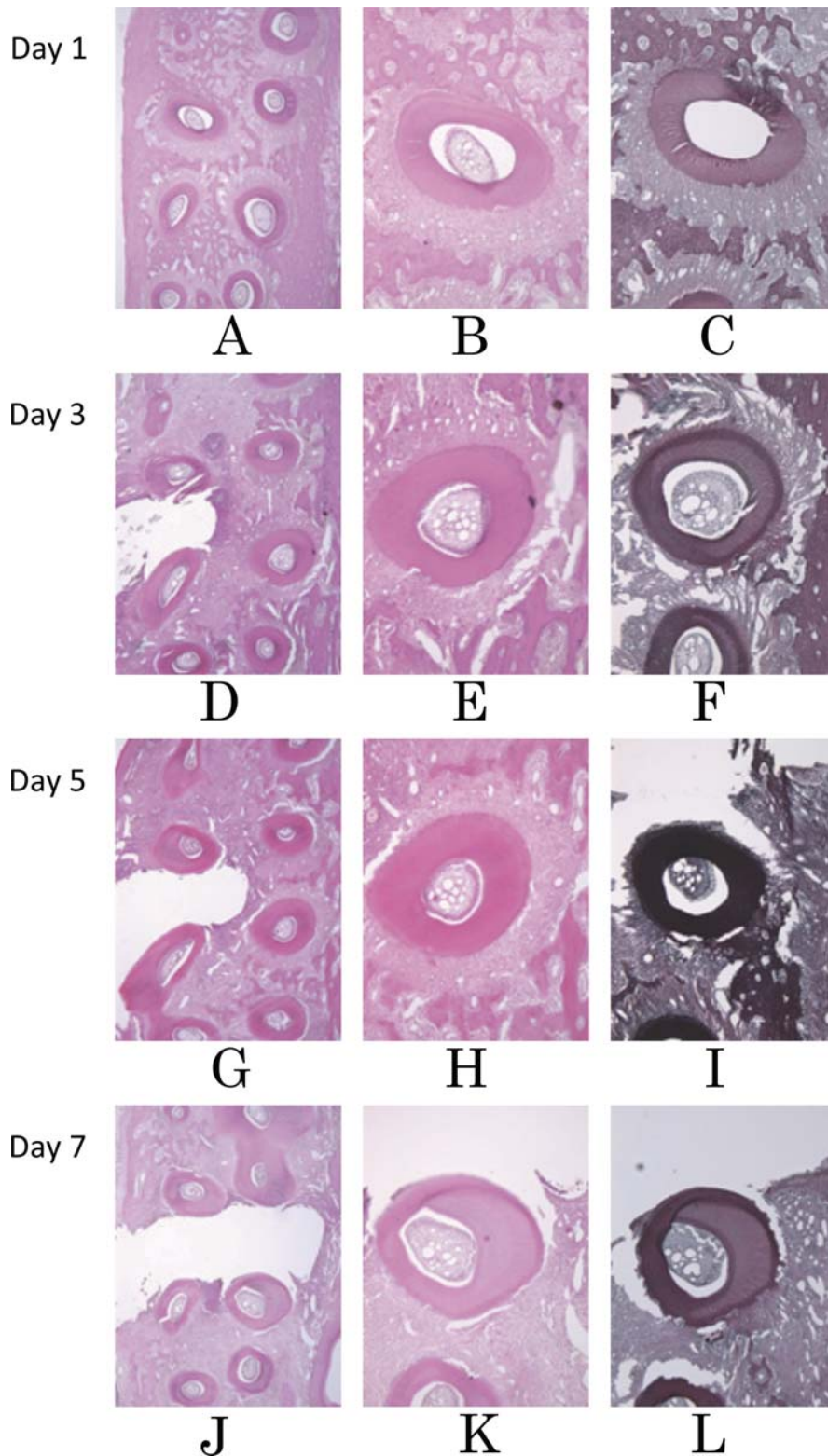
On post-procedure day 1, similar to the findings in the control group, the width of the periodontal ligament in the experimental group narrowed on the pressure side and widened on the tension side (Figs. 6 A and B), and there was marked dilation of the capillaries on the tension side (Fig. 6 B). On day 3, dilation of the capillaries was seen in the periodontal ligament on the pressure side (Figs. 6 D and E). Although the periodontal pockets became more extensive, the pockets (Fig. 6 D) were smaller than in the controls (Fig. 5 D). By day 5, dilation of the capillaries was seen in sites with a strong inflammatory response, and the number of multinucleated giant cells that had formed was small (Figs. 6 G and H). By day 7, the root exposure had become prominent, the periodontal pockets were more extensive than in the controls, and the breakdown of periodontal tissue had become stronger (Fig. 6 J). Resorption lacunae were seen on the root surface on the pressure side (Fig. 6 K).

#### *Silver impregnation staining findings with attachment of elastic rubber bands in the GK rats (experimental group)*

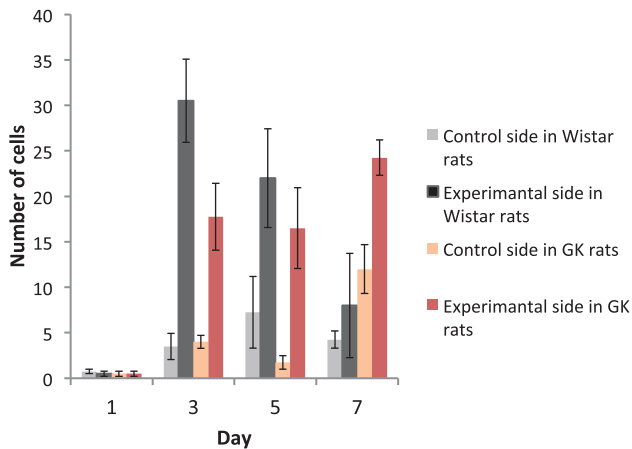
On post-procedural day 1, similar to the control group, the collagen fibers of the periodontal ligament



**Fig. 5** Tissue images in the rubber band attachment group of the Wistar rats. The upper side is proximal in all photos. (A-C) Post-procedure day 1 ; (D-F) Post-procedure day 3 ; (G-I) Post-procedure day 5 ; (J-L) Post-procedure day 7 ; (A, D, G and J) the M1 and M2 rubber insertion sites ; (B, C, E and F) M1 distobuccal root ; (H, I, K and L) M2 mesiopalatal root ; (A, B, D, E, G, H, J and K) HE staining ; and (C, F, I and L) silver impregnation staining. (Original magnification  $\times 33$ , except for A, D, G and J,  $\times 13.2$ ).



**Fig. 6** Tissue images in the rubber band attachment group of the GK rats. The upper side is the proximal in all photos. (A-C) Post-procedure day 1; (D-F) Post-procedure day 3; (G-I) Post-procedure day 5; (J-L) Post-procedure day 7; (A, D, G and J) M1 and M2 rubber insertion sites; (B, C, E and F) M1 distobuccal root; (H, I, K and L) M2 mesiopalatal root; (A, B, D, E, G, H, J and K) HE staining; and (C, F, I and L) silver impregnation staining. (Original magnification  $\times 33$ , except for A, D, G and J,  $\times 13.2$ ).



**Fig. 7** Multinucleated giant cells present in periodontal tissue of maxillary second molar.

were taut on the tension side and relaxed on the pressure side, and dilated capillaries were seen on the tension side (Fig. 6 C). On day 3, the orientation of the collagen fibers in the periodontal ligament was disorientated and the reticular fibers had increased (Fig. 6 F) compared with the controls (Fig. 5 F). By days 5 and 7, the silver impregnation staining of the periodontal ligament had increased compared with the controls (Figs. 5 I and J) and the increase in the reticular fibers had become conspicuous (Figs. 6 I and L).

#### Number of multinucleated giant cells present in the periodontal ligament of M2

On post-procedural day 1, almost no multinucleated giant cells were present and there was no significant difference between the experimental and control groups. Although a tendency was seen for the number of multinucleated giant cells present in the M2 periodontal ligament to reach a maximum on day 3 in the controls, the difference was not found to be significant. In the experimental group, the number of multinucleated giant cells was greater on post-procedural day 7 than on days 3 or 5 (Fig. 7).

#### DISCUSSION

Following tooth movement, the amount of movement and the inter-crown distance from M1 to M3 in the animal model of diabetes was large on post-procedural day 1 in the controls, after which it did not change.

This is thought to be because the periodontal tissue of Wistar rats is healthier and more flexible than that of GK rats.

When teeth are moved with sustained orthodontic force, it is thought that movement occurs in the periodontal space as the first stage, tooth movement subsides with the appearance of hyaline degeneration as the second stage, and then tooth movement occurs again with phagocytic resorption of alveolar bone and degenerated tissue as the third stage.<sup>21</sup> In this study the capillaries on the tension side of the periodontal ligament were dilated on post-procedural day 1 in both the experimental and control groups. Blood supply to the tissue was elevated and an inflammatory response was facilitated. In the controls with healthy and flexible periodontal tissue, the inflammatory response was normal and the breakdown of periodontal tissue progressed. It was therefore thought that extensive periodontal pockets had formed at an earlier stage than in the experimental group, which had decreased metabolic function due to diabetes.

The most conspicuous dilation of the capillaries on the pressure side of the periodontal ligament appeared on day 5 in the controls and on day 3 in the experimental group. Since the end products of advanced glycation promote the synthesis of type IV collagen,<sup>9, 10, 22</sup> the basal lamina, for which type IV collagen is a principal component, thickens.<sup>23</sup> From this it was thought that the capillary walls may have become thicker and the capillaries more rigid. With the attachment of rubber bands, the periodontal ligament is compressed with a strong force and the capillary walls in the ligament stiffen. As a result, it is thought that the capillaries do not break down and dilation occurs on the pressure side at an earlier stage after the procedure than in the controls. It is thought that since the vessel walls are thick, the blood component substances needed to localize inflammation<sup>16</sup> do not make it through the vessel walls in sufficient amounts and the local recovery of inflammation is delayed in the experimental group.<sup>6</sup> The periodontal pockets also become more extensive than in the controls on post-procedural day 7, and periodontal tissue breakdown progresses.

In the periodontal ligament of the experimental

group, the course of the collagen fibers was disrupted after post-procedure day 3. Silver impregnation staining increased compared with the controls, and the amount of reticular fibers increased. It is unlikely that reticular fibers were formed,<sup>11</sup> and it may be that the contraction of the extracellular matrix increased because of the diabetes, and that the larger of the silver particles, which are the staining substance, entered the thin fibers<sup>24, 25</sup> and increased their stainability.<sup>26</sup>

The multinucleated giant cells seen in the M2 periodontal tissue are thought to perhaps be osteoclasts, odontoclasts, or foreign body giant cells. Osteoclasts are associated with bone resorption, odontoclasts with dental root resorption, and foreign body giant cells with phagocytosis of foreign bodies.<sup>27</sup> In this experiment, because staining that could identify these cells was not done, they are described as multinucleated giant cells. On post-procedure day 1, there were almost no multinucleated giant cells in the periodontal ligament of either the experimental or control groups. With attachment of the rubber bands, a tendency was seen in the controls for multinucleated giant cells to reach a maximum on day 3. As a result bone resorption, dental root resorption and foreign body phagocytosis seemed to have reached a peak on that day, and then subsided by day 7.

In the experimental group, because multinucleated giant cells were increased on post-procedure days 3, 5 and 7, it is thought that bone resorption, dental root resorption, and foreign body phagocytosis were delayed as a result of the time needed for the macrophage system cells to incorporate or differentiate to multinucleated giant cells<sup>10, 28</sup> in the state of decreased metabolic function caused by diabetes. In addition, because periodontal pathogenic bacteria increase with elevated glucose concentration in saliva in type II diabetes,<sup>29</sup> it is thought that purulent inflammation was enhanced more in the experimental group than in the controls.

In the case of healthy and flexible periodontal tissue as in the controls, blood flow on the tension side increases with attachment of rubber bands, the inflammatory response occurs normally, and periodontal tissue breakdown progresses at an early stage. Meanwhile, the blood flow on the pressure side increases

over several days and bone resorption, dental root resorption, and foreign body phagocytosis progress at an early stage with the early formation of multinucleated giant cells.<sup>17</sup> Tooth movement is therefore completed at an early stage.

In periodontal tissue with decreased metabolic function as in the experimental group, although blood flow on the tension side increases with the attachment of rubber bands, an inflammatory response is elicited and the breakdown of periodontal tissue progresses. However, the degree of periodontal tissue breakdown in the early stage appears to be milder than in healthy individuals.<sup>30</sup> Although capillaries dilate from an early stage on the pressure side, the basal lamina does not provide sufficient nutritional replenishment with the thickened capillaries, and the formation of multinucleated giant cells is weak. It therefore takes time until bone resorption, dental root resorption, and phagocytosis of foreign bodies are complete.<sup>7</sup> As diabetes progresses, the tertiary structure of connective tissue collagen fibers distorts, swells, and ruptures. As a result, the destruction of periodontal tissue, inducing exposure of the dental root, progresses more than in healthy individuals.<sup>25</sup>

The above suggests that orthodontic treatment in diabetes patients causes changes in the structure of collagen fibers in the connective tissue, as well as a decrease in metabolic function, blood supply volume, and the capacity to form multinucleated giant cells. It therefore should be remembered that tooth movement takes time and the breakdown of periodontal tissue may be significant.

## REFERENCES

1. Melsen B. Limitation in adult orthodontics : Current controversies in orthodontics. Chicago : Quintessence, 1991 : 147-180.
2. Bensch L, Braem M, Van Acker K, Willems G. Orthodontic treatment considerations in patients with diabetes mellitus. *Am J Orthod Dentofacial Orthop* 2003 ; **123** : 74-78.
3. Patel A1, Burden DJ, Sandler J. Medical disorders and orthodontics. *J Orthod* 2009 ; **36** : 1-21.
4. Sakaguchi K. Effects of tooth movement on pulp nerve fibers of the molar in the streptozotocin-induced diabetic rat. *Kyushu Shika Gakkai Zasshi* 1996 ; **50** : 332-348. (Japanese)
5. Noto Y. Critical appraisal of the national health and nutrition survey in Japan 2012. *Diabetes J* 2014 ; **42** : 28-31. (Japanese)
6. Ehara D, Takemura A, Suwa F. Wound healing on palatine mu-



- cosa in the type 2 diabetes mellitus model rats. *J Osaka Dent Univ* 2011 ; **45** : 37-53.
7. Goto Y, Kakizaki M, Masaki N. Production of spontaneous diabetic rats by repetition of selective breeding. *Tohoku J Exp Med* 1976 ; **119** : 85-90.
  8. Takeda Y, Shimomura T, Wakabayashi I. Immunological disorders of diabetes mellitus in experimental rat models. *Nihon Eiseigaku Zasshi*. 2014 ; **69** : 166-176.
  9. Abe H. Recent progress in understanding the molecular pathogenesis of diabetic nephropathy. *Rinsyo Byori*. 2011 ; **59** : 179-186. (Japanese)
  10. Nagase R, Kajitani N, Shikata K, Ogawa D, Kodera R, Okada S, Kido Y, Makino H. Phenotypic change of macrophages in the progression of diabetic nephropathy ; sialoadhesin-positive activated macrophages are increased in diabetic kidney. *Clin Exp Nephrol* 2012 ; **16** : 739-748.
  11. Tabata H, Tominaga K, Ueda M. Formation of type III collagen during early wound healing of periodontal defects in model rats with type II diabetes mellitus. *Jpn J Conserv Dent* 2009 ; **52** : 58-67. (Japanese)
  12. Shigematsu N, Kono T, Ueda M. Relationship between VEGF and AGEs on periodontal wound healing in model rats with type 2 diabetes mellitus. *J Oral Tissue Engin* 2011 ; **9** : 71-80.
  13. Yasuoka R. SEM studies of microangiopathy in the streptozotocin-induced diabetic rat. *Shika Igaku (J Odontol Soc)* 1990 ; **53** : 361-373.
  14. Ishihara E, Takizawa R, Miura T, Usami M. The intake of carbohydrates for the prevention of hypoglycemia in streptozotocin-induced diabetic rat. *Res Rep Suzuka Univ Med Sci* 2007 ; **14** : 31-38. (Japanese)
  15. Waldo CM, Rothblatt JM. Histologic response to tooth movement in the laboratory rat : Procedure and preliminary observations. *J Dent Res* 1954 ; **33** : 481.
  16. Ohnishi R. Immunohistochemical study on the localization of osteocalcin during the experimental tooth movement. *J Jpn Orthod Soc* 1993 ; **52** : 572-577. (Japanese)
  17. Inubushi T. Relationship between initial blood flow changes and histological changes in periodontal tissue during tooth movement. *J Osaka Dent Univ* 1990 ; **24** : 33-62.
  18. Nogimura-Otsuka A. Localization of cathepsin B and L in rat periodontal tissues during experimental tooth movement. *Int J Oral Med Sci* 2004 ; **3** : 1-9.
  19. Taguchi M. Study on prostaglandin E involved in tooth movement. *J Stomatol Soc Jpn* 1987 ; **54** : 106-128. (Japanese)
  20. Tominaga K, Tabata H, Kawanaka A, Wato M, Nishikawa T, Masuno K, Taguchi Y, Matsumoto N, Ueda M, Tanaka A. Immunohistochemical stainability of rat maxillae and intestines immersed in six types of decalcifying solutions. *J Osaka Dent Univ* 2008 ; **42** : 83-87.
  21. Tominaga M. Histopathological study on experimental tooth movement in the spontaneously diabetic rat. *J Fukuoka Dent Coll* 1995 ; **22** : 247-268. (Japanese)
  22. Ueda M, Tanaka A, Ueda M. Immunohistochemical study of the periodontal tissues of model rats with type 2 diabetes mellitus. *J Osaka Dent Univ* 2009 ; **43** : 93-102.
  23. Shinoda Y. Immunohistochemical localization of type IV collagen and laminin in the gingival capillary basement membrane of the diabetic rat. *J Osaka Dent Univ* 1992 ; **26** : 49-66.
  24. Brownlee M, Cerami A, Vlassara H. Advanced glycosylation end-products in tissue and the biochemical basis of diabetic complications. *N Engl J Med* 1988 ; **318** : 1315-1321.
  25. Saoudoun A. Diabetes and periodontal disease. *J West Soc Periodont* 1980 ; **28** : 116-139.
  26. Tominaga K, Masuno K, Takada N, Sakai K, Tanaka A, Kobayashi Y. Effect of the decalcification solution on the reticulin impregnation technique. *Ann Bull Kosei-Nenkin Hosp* 1997 ; **24** : 215-223. (Japanese)
  27. Florencio-Silva R, Sasso GR, Sasso-Cerri E, Simões MJ, Cerri PS. Biology of bone tissue : structure, function, and factors that influence bone cells. *Biomed Res Int* 2015 ; **2015** : 421746. doi : 10.1155/2015/421746
  28. Rothwell B, Richard E. Diabetes mellitus : medical and dental considerations. *Spec Care Dent* 1984 ; **4** : 58-65.
  29. Mascarenhas P, Fatela B, Barahona I. Effect of diabetes mellitus type 2 on salivary glucose – a systematic review and meta-analysis of observational studies. *PLoS One* 2014 ; **9** : e101706. doi : 10.1371/journal.pone.0101706.
  30. Vionnet AC, Jornayvaz FR. Classification of diabetes : an increasing heterogeneity. *Rev Med Suisse* 2015 ; **11** : 1234-1237. (French)