

Pressure of laryngoscope blade on anterior teeth during direct laryngoscopic examination

Hiroki Shibata¹, Yasuhiko Kato², Kazuya Takahashi³ and Yutaka Komasa³

¹Graduate School of Dentistry (Anesthesiology), ²Department of Anesthesiology and ³Department of Geriatric Dentistry, Osaka Dental University, 8-1 Kuzuhahanazono-cho, Hirakata-shi, Osaka 573-1121, Japan

One possible complication of tracheal intubation is injury to the anterior teeth by the laryngoscope blade. We measured pressure where the anterior teeth contacted the blade, and investigated differences in this pressure using six different laryngoscope blades (German design, US design, UK design, English Channel type, reduced flange type and flange-less type). We used a mannequin for intubation training (Laerdal Airway Management Trainer ; Laerdal Medical, Tokyo, Japan) and a German bite pressure meter (Nihon Kohden Corporation, Tokyo, Japan). Each laryngoscope blade was used 30 times to perform direct laryngoscopic exposure, and we measured the maximum pressure of the laryngoscope blade on the contact site of the anterior teeth when a Cormack Grade I larynx field of vision had been secured. Because the field of vision of the larynx could be obtained with the flange-less type laryngoscope blade without any contact with the anterior teeth, it was excluded from this analysis.

Statistical analysis performed using multiple comparisons (Tukey-Kramer method, $p < 0.05$) showed that contact pressure with the reduced flange type laryngoscope was significantly less than with the other types. These results suggest that laryngoscopes with a narrow blade width cause less pressure and therefore a smaller burden on the contact site of the anterior teeth. (J Osaka Dent Univ 2015 ; 49(1) : 123–128)

Key words : Pressure ; Anterior teeth ; Laryngoscope blade

INTRODUCTION

When performing laryngoscopy during the induction of general anaesthesia, the laryngoscope is inserted intraorally by displacing the tongue. During this process, the upper incisors may come into contact with the blade, thereby damaging the teeth. In terms of clinical statistics, about 1 in 2,000 patients (0.05%) reportedly sustain oral injuries from general anaesthesia, among which risk of damage to the maxillary central incisors is especially high.¹ In Japan, damage to teeth associated with intubation is reported in about 0.4% of cases.^{2,3} General anaesthesia is often used for dental treatment or orthodontics, and the utmost effort should be made to avoid damage to the teeth.

Various studies have been published regarding the ease of use of the laryngoscope blade (hereafter referred to as the blade) and damage to the teeth.⁴⁻⁶

However, to the best of our knowledge, there have been no studies regarding the load placed on the anterior teeth by the blade.

In this experiment, we measured the load applied to the point of contact between the blade and the maxillary anterior teeth during laryngoscopy. We also examined differences in load depending on the type of blade.

MATERIALS AND METHODS

In this experiment, we used six different types of Macintosh Blades : the English Profile, American Profile, 'G' Profile, English IV MAC, Reduced Flange and Flange-Less MAC (Fig. 1). Figure 2 shows the measurement parts for blade height and flange width (Fig. 2). 'Height' refers to the width of the blade in the vertical direction with respect to the tooth axis at the point of contact, while 'flange' refers to the width of the




Fig. 1 Laryngoscope blades used.




Fig. 2 (A) Flange Height, (B) Flange width.

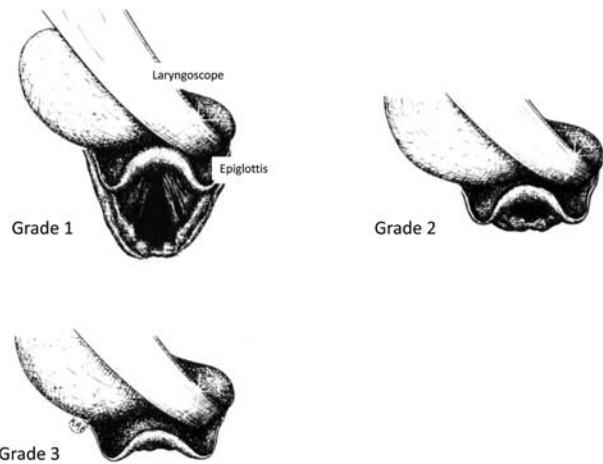


Fig. 3 Cormack-Lehane classification system for laryngoscopy (partially modified).

blade in the horizontal direction with respect to the tooth axis at the point of contact. Mannequins for intubation practice (Laerdal Airway Management Trainer ; Laerdal Medical, Tokyo, Japan) were used for the experiment. An occlusal force meter (MPM-3000 Nihon Kohden Corporation, Tokyo, Japan) was used as the measuring instrument. This force meter has a cord. There is sensor on the tip of the cord that is 13 mm in diameter and 3 mm thick.

We could obtain the moment and maximum pressure from the start to the end for measurement.

In this report, we used the maximum pressure.

A dental anaesthesiologist with the equivalent of 4

years' clinical experience performed laryngoscopy 30 times with each blade and measured the maximum load (kg) applied at the point of contact between the blade and the anterior teeth once the laryngeal view had been established in accordance with Grade 1 of the Cormack and Lehane classification system⁷ (Fig. 3). Multiple comparison (Tukey-Kramer method, $p < 0.05$) was used for statistical processing. In addition, the load applied to the anterior tooth contact point by the English Profile blade used at our hospital was

recorded over time from the point at which it was inserted intraorally until Grades 3 to 1 were reached. The distance between the blade and the point of contact with the tissue, as well as the amount of displacement, were measured using computed tomography (CT) scans (A 16 Row MDCT Bright Speed Elite ; GE Healthcare, Milwaukee, WI, USA) taken at the time of laryngoscopy.

RESULTS

Because the laryngeal view is acquired without contact with anterior teeth when using the Flange-Less blade, it was excluded from our study sample. The loads applied by the other blades were as follows : English Profile : 100.6 ± 19.0 kg, American Profile : 111.7 ± 17.7 kg, 'G' Profile : 99.6 ± 16.4 kg, English IV MAC : 108.9 ± 19.2 kg, and Reduced Flange : 63.6 ± 20.8 kg (Table 1). The results of the multiple comparison test revealed that the contact load of the Reduced Flange blade was significantly less than with the other blades (Fig. 4). Changes in load over time with the English Profile blade were 73.6 kg at Grade 3, 117.2 kg at Grade 2 and 121.8 kg at Grade 1 (Fig. 5). The epiglottal area was displaced 2.7 cm on CT by laryngoscopy (Fig. 7).

DISCUSSION

Laryngeal view is achieved during laryngoscopy by physically displacing the tissue of the oral cavity and pharynx with the laryngoscope. In doing this, the axes of the pharynx and oral cavity are aligned. The Cormack-Lehane classification can be used to assess laryngeal view during laryngoscopy. In this experiment, Grade 1, in which a full view of the glottis is established, was used as the standard for laryngoscopy.

The intubation guidelines of the British Difficult Airway Society specify the frequency of use of laryngoscopes and laryngeal masks.⁹ Performing intubation more than necessary poses the risk of damage to soft tissues of the oral cavity due to external force as well as swelling. Swelling of the airway puts the patient at direct risk of suffocation. The regulations regarding the frequency of use of laryngoscopes and laryngeal masks in the guidelines are for the purpose of pre-

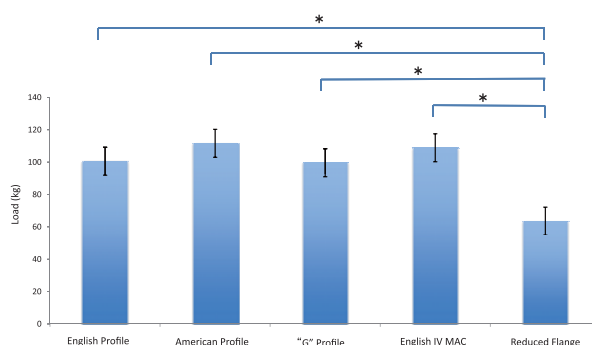


Fig. 4 Average load applied to the point of contact by the Reduced Flange Macintosh was significantly less than that of the other blades. * $p < 0.05$, I standard deviation.

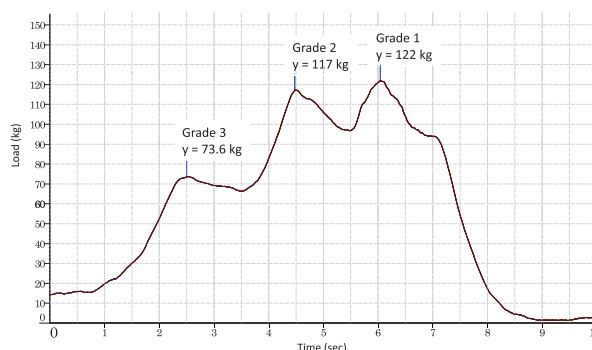


Fig. 5 Change over time in the load applied with the English Profile blade.

Table 1 Flange width and height, and the load of each blade

Blade	Flange width (mm)	Flange height (mm)	Average \pm 1 SD (kg)
Macintosh Blade English Profile	13	23	100.6 ± 19.0
American Profile Macintosh Blade	12	24	111.6 ± 17.7
'G' Profile Macintosh Blade	15	20	99.6 ± 16.4
English IV MAC	13	24	108.8 ± 19.1
Reduced Flange Macintosh	none	15	63.5 ± 20.7
Flange-Less MAC	none	7	-

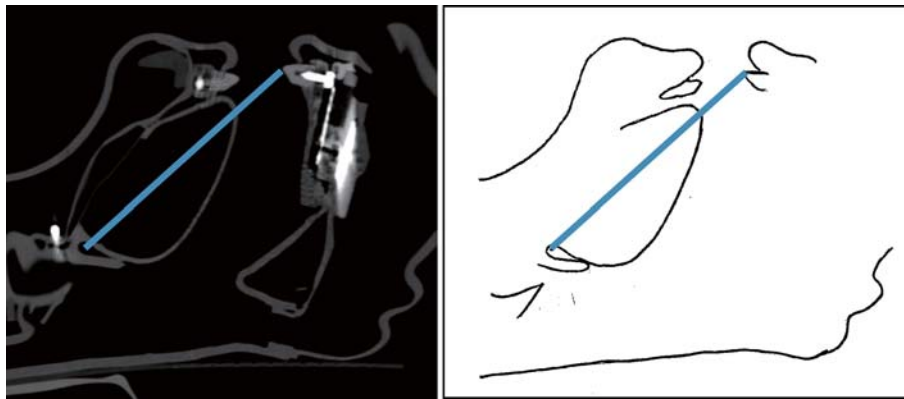


Fig. 6 CT scan at rest. Distance from tip of the incisor to the epiglottal area is 9.0 cm.

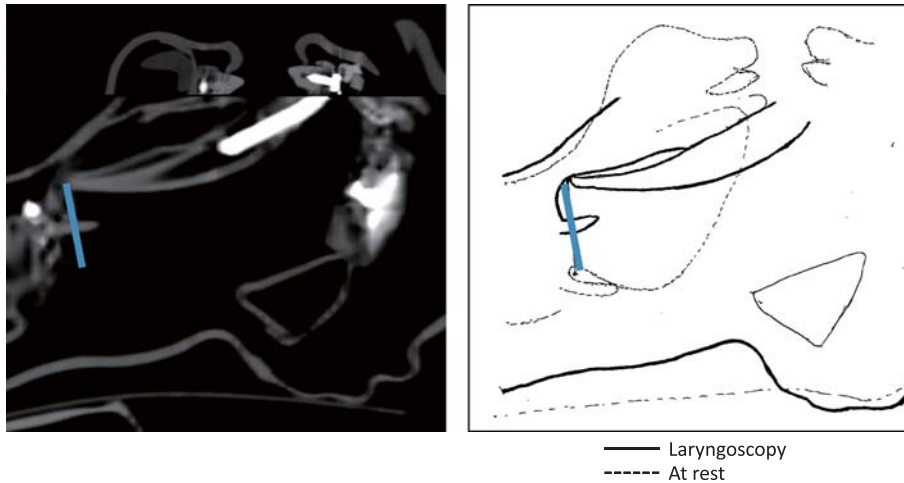


Fig. 7 Superimposed CT scans at rest and during laryngoscopy. The epiglottal area was displaced forward 2.7 cm.

venting damage to the airway. For this reason, we used mannequins in the present study instead of live specimens due to the risks involved.

CT measurements revealed that the distance from the epiglottal area to the incisors at rest was 9.0 cm (Fig. 6). When the laryngoscope blade comes into contact with an incisor during laryngoscopy, the laryngoscope is inserted to invert the epiglottis and displace the tongue and the point of contact with the incisor is used as a support point. The laryngeal area and tongue are then displaced upward as a result of the rotation and pulling. Leverage results in the depression force being placed on the incisors. CT images revealed that the displacement of the epiglottal area due to laryngoscopy was 2.7 cm (Fig. 7). Furthermore, the

distance (C'-D'') from the edge of the blade (C) to the point of contact with the incisor (D) is assumed to be the distance from the epiglottal area at rest to the edge of the blade (9.0 cm). The vertical distance (D'-E') from the point of contact with the incisor (D) to the grip of the blade (E) is about 3.0 cm, with a calculated ratio of C'-D' : D'-E' of 3 : 1 (Fig. 8). Thus, assuming a support point of E'' with the English Profile blade, a depression force of 100.6 kg is applied at the point of contact with the incisor, a resistance force of 25.2 kg is applied to the tip of the blade by the surrounding tissue when the epiglottal area is displaced 2.7 cm, and a force of 75.6 kg is applied to the grip.

We will now describe the characteristics of the blades used in this experiment.

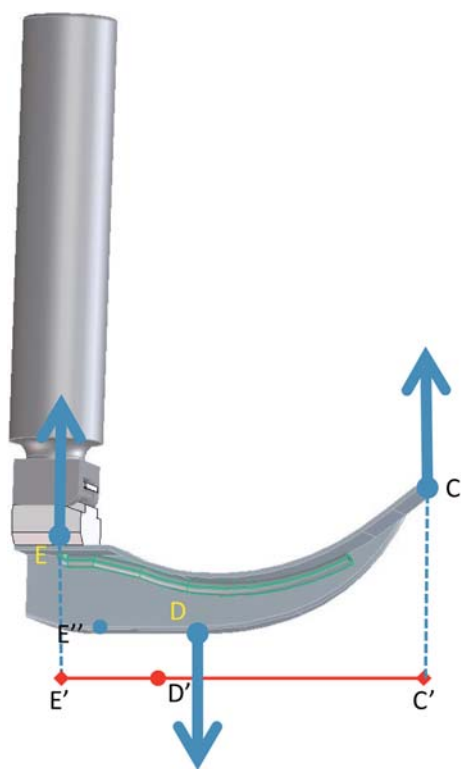


Fig. 8 Laryngoscope.
 C : Blade tip, D : Point of contact point with the incisor, E : Grip, C'-D' : 9.0 cm, D'-E' : 3.0 cm

English Profile and American Profile blades have a generic shape. The “G” PROFILE blade has more optical fibers than the other blades because the fibers are cast together with the blade, making it brighter and easier to clean. The English IV blade is an English Profile blade that is rounded at the bottom, offering better visibility than the English Profile design. The Reduced Flange blade has a narrower width flange to avoid contact with the teeth.

The Flange-Less MAC blade is designed so that it can be used in cases of lockjaw. The Reduced Flange blade has no flange, whereas other blades have a flange width of 12–15 mm. The blade height is also reduced to 15 mm, compared with greater than 20 mm in other blades. The shape of the blade is curved upwards slightly to facilitate an epiglottal approach. As a result, the distance from the tip of the blade, which is the point of action, to the point of contact, which serves as the support point, is greater the taller the blade is. The force applied to the support point increases de-

pending on this distance. In this experiment, the load applied at the point of contact was lower with the Reduced Flange blades than with the others.

The change in load over time with the English Profile blade increased approximately 1.6-fold from Grade 3 to Grade 2 and approximately 1.7-fold from Grade 3 to Grade 1. This suggests that the load placed on the tooth by the blade is greater in the latter half of the intubation process. In the Cormack-Lehane classification system, a smaller grade indicates a better laryngeal view. This is also related to the amount of inversion of the epiglottis. In other words, a smaller the grade indicates more displacement of the epiglottal area, which may increase the load placed on the support point.

In this experiment, the same surgeon tested each blade using the same mannequin to examine the differences in load. However, in actual clinical practice, there are patients with restricted retroflexion of the head and patients with a larger volume of intraoral tissue. Samssoon et al. report that the Mallampati classification used as an index for predicting intubation difficulty is clinically consistent with the Cormack-Lehane classification for laryngoscopy.⁸ During intubation, the surgeon aims for Grade 1 laryngoscopy in order to obtain a better view. Consequently, a larger load is placed on the incisor to achieve Grade 1 in cases where a laryngeal view is difficult to obtain. In cases where intubation is expected to be difficult, a smaller blade should be selected beforehand to reduce the load placed on the point of contact with the incisor.

A blade of the appropriate height and a surgeon skilled in intubation are both necessary to establish a laryngeal view and to reduce the load placed on the incisors. Although teeth are strong, if the supporting tissues are weakened by periodontitis, there is an increased risk of damage to the teeth during intubation. In such cases, it is necessary to pay extra attention to the point of contact with the incisors and to ensure that the blade does not come into direct contact with the teeth. To date, a number of methods of preventing tooth damage have been reported, including development of Flange-Less blades, and avoidance of direct contact between the blade and teeth through the use of gauze and mouth guards.^{2,3,9-12} Moreover,

protecting the teeth during intubation is reportedly linked to patient comfort.² Our findings suggest that it is necessary for surgeons to consider the effect of intubation on the teeth when applying tension and using supplementary tools.

CONCLUSION

The results of this study suggest that the load placed on the anterior teeth is less when a laryngoscope with a narrower blade is used. Precautions must be taken to ensure safe intubation without damaging the teeth.

CT images and their data were obtained courtesy of the Department of Oral Radiology, Osaka Dental University.

REFERENCES

1. Newland MC, Ellis SJ, Peters KR, Simonson JA, Durham TM, Ullrich FA, Tinker JH. Dental injury associated with anesthesia : a report of 161,687 anesthetics given over 14 years. *J Clin Anesth* 2007 ; **19** : 339–345.
2. Nakahashi K, Yamamoto K, Tsuzuki M, Tatebayashi S, Morimoto Y, Kitaguchi K, Furuya H. Effect of teeth protector on dental injuries during general anesthesia. *Masui* 2003 ; **52** : 26–31. (Japanese)
3. Ueda N, Kirita T, Imai Y, Inagake K, Matsusue Y, Inoue S, Kawaguchi M, Furuya H. Dental injury associated with general anesthesia and its preventive measures. *Masui* 2010 ; **59** : 597–603. (Japanese)
4. Rassam S, Wilkes AR, Hall JE, Mecklenburgh JS. A comparison of 20 laryngoscope blades using an intubating manikin : visual analogue scores and forces exerted during laryngoscopy : *Anesthesia* 2005 ; **60** : 384–394.
5. Jobst V, Stefan S, Markus K, Gabriel K, Andreas F. Dental injuries resulting from tracheal intubation – a retrospective study. *Dent Traumatol* 2009 ; **25** : 73–77.
6. Mourao J, Neto J, Luis C, Brbosa J, Carvalho J, Tavares J. Dental injury after conventional direct laryngoscopy ; a prospective observational study. *Anesthesia* 2013 ; **68** : 1059–1065.
7. Cormack RS, Lehane J. Diffucult tracheal intubation in obstetrics. *Anesthesia* 1984 ; **39** : 1105.
8. Samsoun GL, Young JR. Difficult tracheal intubation : a retrospective study. *Anesthesia* 1987 ; **42** : 487.
9. Henderson JJ, Papat MT, Latto IP, Pearce AC. Difficult Airway Society guidelines for management of the unanticipated difficult intubation. *Anaesthesia* 2004 ; **59** : 675–694.
10. Monaca E, Fock N, Doehn M, Wappler F. The effectiveness of preformed tooth protectors during endotracheal intubation : an upper jaw model. *Anesth Analg* 2007 ; **105** : 1326–1332.
11. McFadden LR, O'Donnell JM, Rose CE. Dental guards : helpful or hazards? –a case report. *AANA J* 2000 ; **68** : 127–130.
12. Sinha PK, Arora S, Gombar KK. Another teeth protector. *Anesthesia* 2000 ; **55** : 920–921.
13. Lee J, Choi JH, Lee YK, Kim ES, Kwon OK, Hastings RH. The Callander laryngoscope blade modification is associated with a decreased risk of dental contact. *Can J Anaesth* 2004 ; **51** : 181–184.