

## Chemopreventive effect of green tea catechin on rat tongue carcinogenesis induced by 4-nitroquinoline 1-oxide

Takako Kono<sup>1</sup>, Yuki Matsushima<sup>2</sup> and Shosuke Morita<sup>2</sup>

<sup>1</sup>Graduate School of Dentistry (First Department of Oral and Maxillofacial Surgery) and <sup>2</sup>First Department of Oral and Maxillofacial Surgery, Osaka Dental University, 8-1 Kuzuhahanazono-cho, Hirakata-shi, Osaka 573-1121, Japan.

Oral cancer treatment may have significant adverse effects on the patient's activities of daily living (ADL) and quality of life (QOL). In recent years attention has been focused on the use of food for chemoprevention. (–)-Epigallocatechin-3-gallate (EGCG), which accounts for about half of green tea catechins, is not only a strong antioxidant, but has also been reported to possess anti-tumor and carcinogenesis-inhibiting actions. As the oral mucosa comes into direct contact with green tea, its carcinogenesis-inhibiting action may be effective against oral cancer. We investigated the carcinogenesis-inhibiting activity of EGCG in the carcinogenic process in rats with tongue cancer induced by 4-nitroquinoline 1-oxide (4NQO).

Sprague-Dawley (SD) rats were given water containing either a 50-ppm aqueous solution of 4NQO to induce tongue cancer or the 4NQO solution together with a 500-ppm aqueous solution of EGCG. A control group was given only distilled water. Macroscopic observations and histopathologic comparisons were made of the back of the tongue at 8, 12, 16, 20 and 24 weeks after the start of administration. The association between activated nuclear factor  $\kappa$ B (NF- $\kappa$ B) p65 and I $\kappa$ B kinase  $\alpha$  (IKK $\alpha$ ) expression and tumor growth in the carcinogenic process was investigated by immunohistochemical staining and immunoblotting.

The administration of EGCG not only significantly suppressed the occurrence of epithelial dysplasia and squamous cell carcinoma in rats with 4NQO-induced tongue cancer, but also inhibited the expression of activated (NF- $\kappa$ B) p65 and IKK $\alpha$  ( $p < 0.05$ ). It also decreased the proportion of Ki-67-positive cells, and inhibited cell proliferative activity ( $p < 0.05$ ). Western blotting was performed for these proteins, and the same results were also obtained for their expression via immunostaining.

These results suggest that the carcinogenesis-inhibiting action of EGCG is probably due to the inhibition of activated NF- $\kappa$ B p65, and that long-term administration of EGCG may decrease IKK $\alpha$  expression, increasing its activity in suppressing the promotion of carcinogenesis and suppressing multi-step carcinogenesis. (J Osaka Dent Univ 2014 ; 48(1) : 37–47)

**Key words :** Chemoprevention ; (–)-Epigallocatechin-3-gallate ; NF- $\kappa$ B p65 ; 4-Nitroquinoline 1-oxide ; Carcinogenesis

### INTRODUCTION

Treatments for oral cancer may have significant adverse effect on the patient's activities of daily living (ADL) and quality of life (QOL). However, foods may offer potential for chemoprevention. In recent years, attention has been focused on the anti-tumor and

carcinogenesis-inhibiting actions of green tea. (–)-Epigallocatechin-3-gallate (EGCG), the main component of green tea catechins, has been shown to exert a particularly pronounced carcinogenesis-inhibiting effect even among catechins. However, many issues concerning its mechanism remain unclear.

Nuclear factor  $\kappa$ B (NF- $\kappa$ B) p65 is a protein complex

that is involved in cell proliferation and division. It is known that activation of NF- $\kappa$ B p65 contributes to the carcinogenic transformation of cells. The I $\kappa$ B kinase  $\alpha$  (IKK $\alpha$ ) gene activates NF- $\kappa$ B p65, controlling the proliferation of squamous cell carcinoma cells and intercellular signal transduction. For this reason the dynamics of IKK $\alpha$  and NF- $\kappa$ B p65 in squamous cell carcinoma have been a focus of attention for their contribution to tumor progression.

It has recently been reported that EGCG inhibits the activation of NF- $\kappa$ B p65, which is believed to be an important regulatory factor in carcinogenesis. However, it has yet to be ascertained how EGCG administration causes changes in the expression of activated NF- $\kappa$ B p65. We investigated the carcinogenesis-inhibiting activity of EGCG in the carcinogenic process in rats with tongue cancer induced by 4-nitroquinoline 1-oxide (4NQO).

## MATERIALS AND METHODS

### Experimental animals and production of experimental reagents

A total of 165 six-week-old Sprague-Dawley (SD) male rats (Shimizu Laboratory Supplies, Kyoto, Japan) were used in this experiment, of which 150 were in the experimental groups and 15 were controls. The animals were reared in cages at  $24 \pm 0.5^\circ\text{C}$  in the animal care facility of the Institute of Dental Research of Osaka Dental University, and were fed Oriental Solid Chow MF (Oriental Yeast, Osaka, Japan) for the duration of the experiment.

Each of the three experimental groups (A, B and C) included 50 animals (Fig. 1). From week 2 of the

experiment, rats in Group A were given distilled water containing 4NQO (Nacalai Tesque, Kyoto, Japan) diluted to 50 ppm for 12 weeks. They were then given distilled water to drink for the duration of the experiment. Rats in Group B were given the same 4NQO solution as Group A for 12 weeks, together with EGCG (Taiyo Kagaku, Yokkaichi, Mie, Japan) diluted to 500 ppm in distilled water. The duration of the experiment was 24 weeks for both Groups A and B. Group C was given EGCG solution as drinking water for a 36-week experimental period with 4NQO solution given between 12 and 24 weeks. The control group was given distilled water only. The animals were anesthetized by isoflurane inhalation and euthanized by pentobarbitol overdose at 8, 12, 16, 20 and 24 weeks after the start of administration of the 4NQO solution, and the tongue tissue was harvested. This experiment was approved by the Osaka Dental University Animal Experiment Committee (Approval No 12-04008) and performed in compliance with guidelines on animal experiments.

### Macroscopic and histopathologic observations

Harvested samples were examined macroscopically in an area approximately 1 cm anterior to the vallate papilla of the rat tongue. They were then fixed by 24-h immersion in 4% paraformaldehyde (PFA) by the standard method, embedded in paraffin, and cut into 3- $\mu$ m thin slices. Hematoxylin-eosin staining was used to observe histopathologic changes.

### Immunohistochemical staining

Immunostaining was performed on 3- $\mu$ m slices from each group at the time of harvesting. After deparaffinization by the standard method, the slices were immersed in 0.01 M citrate buffer solution (pH 6.0) and subjected to antigen retrieval treatment in an autoclave at  $121^\circ\text{C}$  for 15 min. Endogenous peroxidase activity was then deactivated with 0.3% hydrogen peroxide, and blocking treatment was carried out by reacting the samples for 10 min with Protein Block, Serum-Free (Dako North America, Carpinteria, CA, USA) for phospho-NF- $\kappa$ B p65 antigen and IKK $\alpha$  antigen. After reaction at room temperature for 60 min with a 1 : 200 dilution of anti-phospho-NF- $\kappa$ B p65 (Ser

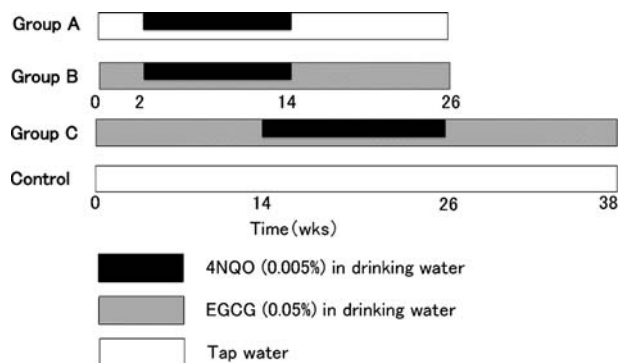


Fig. 1 Experimental protocol.

536) monoclonal antibody (93H10 ; Cell Signaling Technology, Danvers, MA, USA), a 1 : 200 dilution of IKK $\alpha$  polyclonal antibody (SC-7218 ; Santa Cruz Biotechnology, Santa Cruz, CA, USA), or a 1 : 100 dilution of anti-Ki-67 monoclonal antibody (MIB-5 ; Dako, Glostrup, Denmark) as primary antibodies, samples were reacted with Dako LSAB2 kit/HRP (Dako) as the secondary antibody, and the color was developed with 3,3'-diaminobenzidine-tetrahydrochloride (DAB). Nuclear staining was performed with hematoxylin, and after dehydration and infiltration the samples were mounted and examined microscopically. Normal mouse serum was used instead of the primary antibodies in the immunoreaction controls.

### **SDS-PAGE and western blotting**

Rat tongue tissue harvested from each group at 12, 16 and 24 weeks was tested by SDS-polyacrylamide gel electrophoresis (SDS-PAGE) and western blotting to reveal the proteins contained in the samples. Rat tongue tissue was dissolved in sample buffer (9 M urea, 2% triton X-100, 1% dithiothreitol [DTT], 10% SDS, and 50 mM Tris [pH 8.0]), and subjected to ultrasound processing for use in electrophoresis. The amount of protein in samples was measured using the Bradford assay (Bio-Rad Laboratories, Hercules, CA, USA), and the samples were adjusted so that total protein was 450  $\mu$ g. SDS-PAGE was performed on 10% polyacrylamide gels, and proteins were blotted onto a polyvinylidene difluoride (PVDF) membrane (Immobilon ; Millipore, Bedford, MA, USA). After blocking, the PVDF membrane was reacted overnight at 4°C with anti-phospho-NF- $\kappa$ B p65 and anti-IKK $\alpha$  as the primary antibodies. ECL : HRP labeled antibodies were used as secondary antibodies, and detection was carried out using an ECL kit (Amersham Pharmacia Biotech UK, Buckinghamshire, UK). Normal mouse serum was used instead of the primary antibodies in the immunoreaction controls.

### **Statistical analysis**

The incidence of lesions was calculated and compared from macroscopic and histopathologic observations. The labeling index (LI) was also calculated for immunohistochemical staining samples. Cells in

which the nucleus was stained were classified as positive, and the LI was calculated from the number of positive cells counted among approximately 500 epithelial cells in typical tissue from each group within the field of vision under light microscopy at 400 X magnification. Student's t-test was used to test the statistical significance of differences between the various groups.

## **RESULTS**

### **Systemic signs**

The rats tolerated the oral administration of 4NQO and EGCG well during the experimental period, with no animals exhibiting clinical symptoms of toxicity. There were no histopathologic signs of EGCG-induced toxicity in major organs.

### **Macroscopic and histopathologic observations**

#### ***Association between macroscopic and histopathologic tongue findings***

Obvious leukoma (leukomatous lesions) was evident on the back of the root of the tongue from 8 weeks after the start of 4NQO administration. By week 12, the filiform papillae had disappeared, and somewhat concave reddish lesions (erythematous lesions) had appeared in the surroundings. Lesions with associated ulceration (ulcerated lesions) and everted mass-like lesions (tumorous lesions) appeared from 16 weeks.

Histopathologically, the leukomatous lesions exhibited hyperkeratosis of the stratum corneum, and the nuclei of the stratum spinosum had become transparent. There was no polarization or atypical cells of the stratum basal, and epithelial hyperplasia was evident. These changes were limited to the superficial epithelial layer, with no development into the deeper layers or externally, and the lesions exhibited flat proliferative morphology. In the erythematous lesions, the stratum corneum was thinned or missing, and there was evident thickening of the stratum spinosum and loss of polarity of the stratum basal, with mild or moderate epithelial dysplasia. Cells were markedly atypical in places, with severe epithelial dysplasia and carcinoma in situ present. Although there was no infiltration of the lamina propria, developmental morphol-

ogy of the cells exhibited downgrowth proliferation. Ulcerative lesions exhibited infiltration of cancer cells into connective tissue, with dyskeratosis and increased atypical cells. Tumorous lesions exhibited a tendency for pronounced dyskeratosis, with the formation of well differentiated squamous cell carcinoma (Table 1).

### ***Incidence of macroscopic lesions on the tongue***

The incidence of leukomatous lesions was 14 animals (28%) in Group A, 27 (54%) in Group B, and 22 (44%) in Group C. Erythematous lesions were present in 11 animals (22%) in Group A, 9 (18%) in Group B, and 3 (6%) in Group C. Ulcerative lesions were present in 13 animals (26%) in Group A, but were not observed in Groups B or C (0% ; 100% inhibition), both significantly lower than Group A ( $p < 0.05$ ). Although there was no causal relationship between the incidence of erythematous lesions and malignant transformation, almost all ulcerative lesions had become

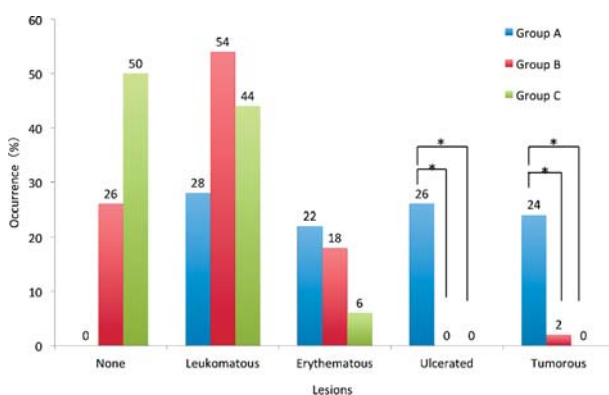
malignant. Tumorous lesions were present in 12 animals (24%) in Group A and 1 (2%) in Group B, but were not observed in Group C (0% ; 100% inhibition) ( $p < 0.05$ ) (Fig. 2).

### ***Incidence of histopathologic lesions on the tongue***

The incidence of epithelial hyperplasia was 16 animals (32%) in Group A, 23 (46%) in Group B, and 21 (42%) in Group C, indicating that administration of EGCG clearly causes an increase. The incidence of severe dysplasia was 5 animals (10%) in Group A. Mild epithelial dysplasia was common in Group B (12%). However, in Group C mild and moderate epithelial dysplasia decreased and severe epithelial dysplasia was completely absent. The incidence of carcinoma in situ and squamous cell carcinoma was 23 animals (46%) in Group A. However, it was only 2 (4%) in Group B, and it did not occur at all in Group C (0% ; 100% inhibition) ( $p < 0.05$ ) (Fig. 3).

**Table 1** Macroscopic and histopathologic observations

Time (wks)	Macroscopic observations	Histopathologic observations
8	Leukomatous lesions	Epithelial hyperplasia
12	Erythematous lesions	Epithelial dysplasia (mild, moderate)
16~	Ulcerated lesions Tumorous lesions	Epithelial dysplasia (severe) Carcinoma in situ Squamous cell carcinoma

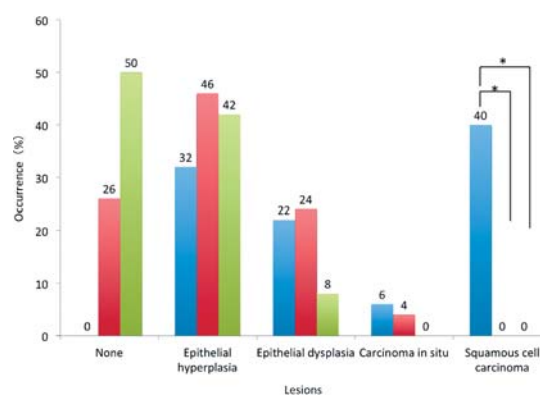


**Fig. 2** Macroscopic observations in rats treated with 4NQO and EGCG. \* $p < 0.05$ , Mean  $\pm$  SD.

### ***Immunohistochemical findings for phospho-NF- $\kappa$ B p65 and IKK $\alpha$ proteins***

#### ***Localization of phospho-NF- $\kappa$ B p65-positive cells***

NF- $\kappa$ B p65 immunostaining was performed using an antibody that specifically recognized the phosphorylation of the serine 536 residue (Ser 536) on the NF- $\kappa$ B subunit (activated NF- $\kappa$ B ; phospho-NF- $\kappa$ B p65). In the control group, phospho-NF- $\kappa$ B p65 was expressed within the nuclei of some cells distributed

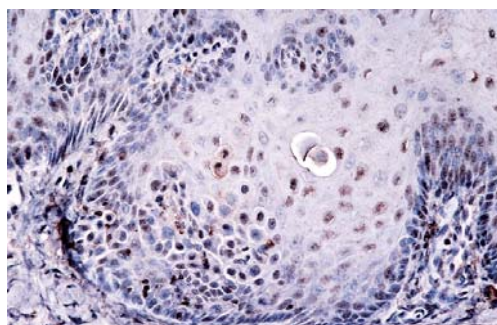


**Fig. 3** Histopathologic observations in rats treated with 4NQO and EGCG.

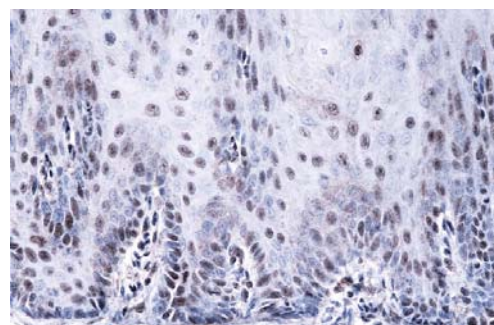
from the stratum basal to the stratum spinosum.

In Group A, 12 weeks after 4NQO administration, positive cells were observed from the stratum basal to the stratum spinosum, in the nuclei and cytoplasm of some cells. The extent of such positive cells gradually expanded at weeks 16 and 20, with expression observed throughout the stratum spinosum. In cancer tissues at week 24, there was strong expression within the nuclei of cells at the margin of the cancer foci, whereas cytoplasmic expression decreased. In Group B, positive expression was localized in the nu-

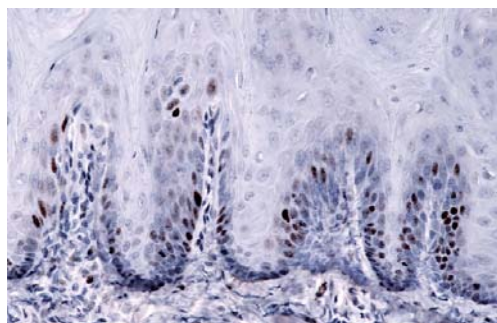
clei and cytoplasm of the stratum basal, but rapidly expanded from 16 weeks on, and by 24 weeks there was strong expression within the nuclei of cells at the margin of the cancer foci, whereas cytoplasmic expression had decreased. In Group C, the distribution of positive cells was little different from that seen in the controls, with expression evident in the cytoplasm of cells in the stratum basal and part of the stratum spinosum (Fig. 4).



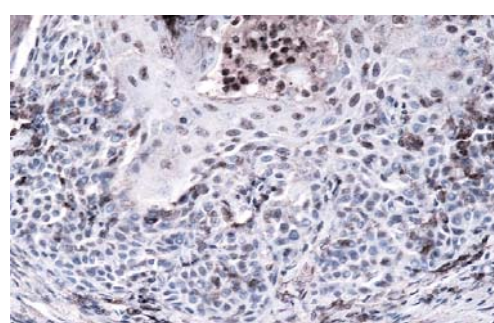
A



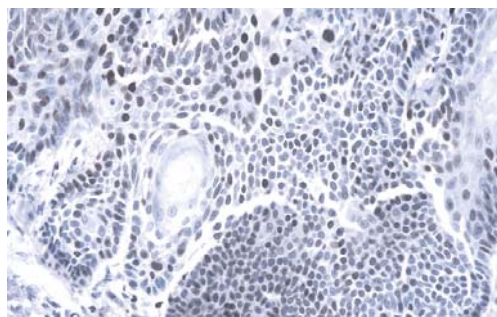
B



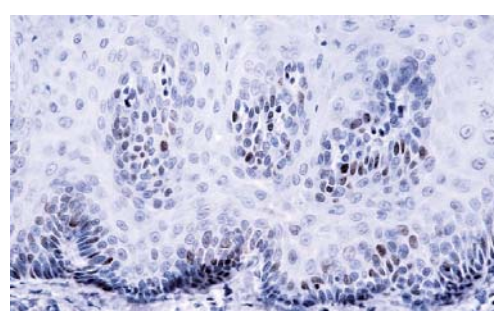
C



D



E

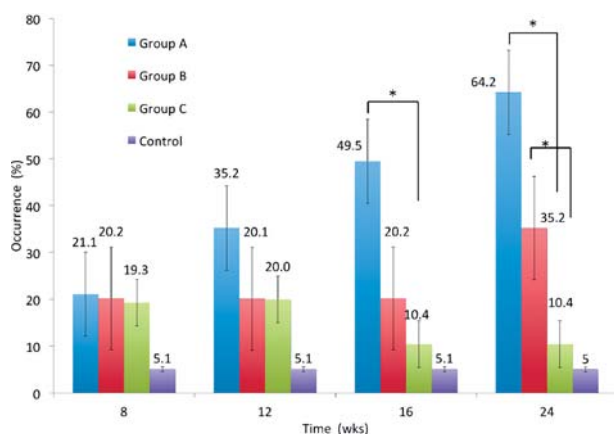


F

**Fig. 4** Immunohistochemical staining of phospho-NF-κB p65

A : Group A at 16 wks, B : Group B at 16 wks, C : Group C at 16 wks, D : Group A at 24 wks, E : Group B at 24 wks, F : Group C at 24 wks ( $\times 100$ )

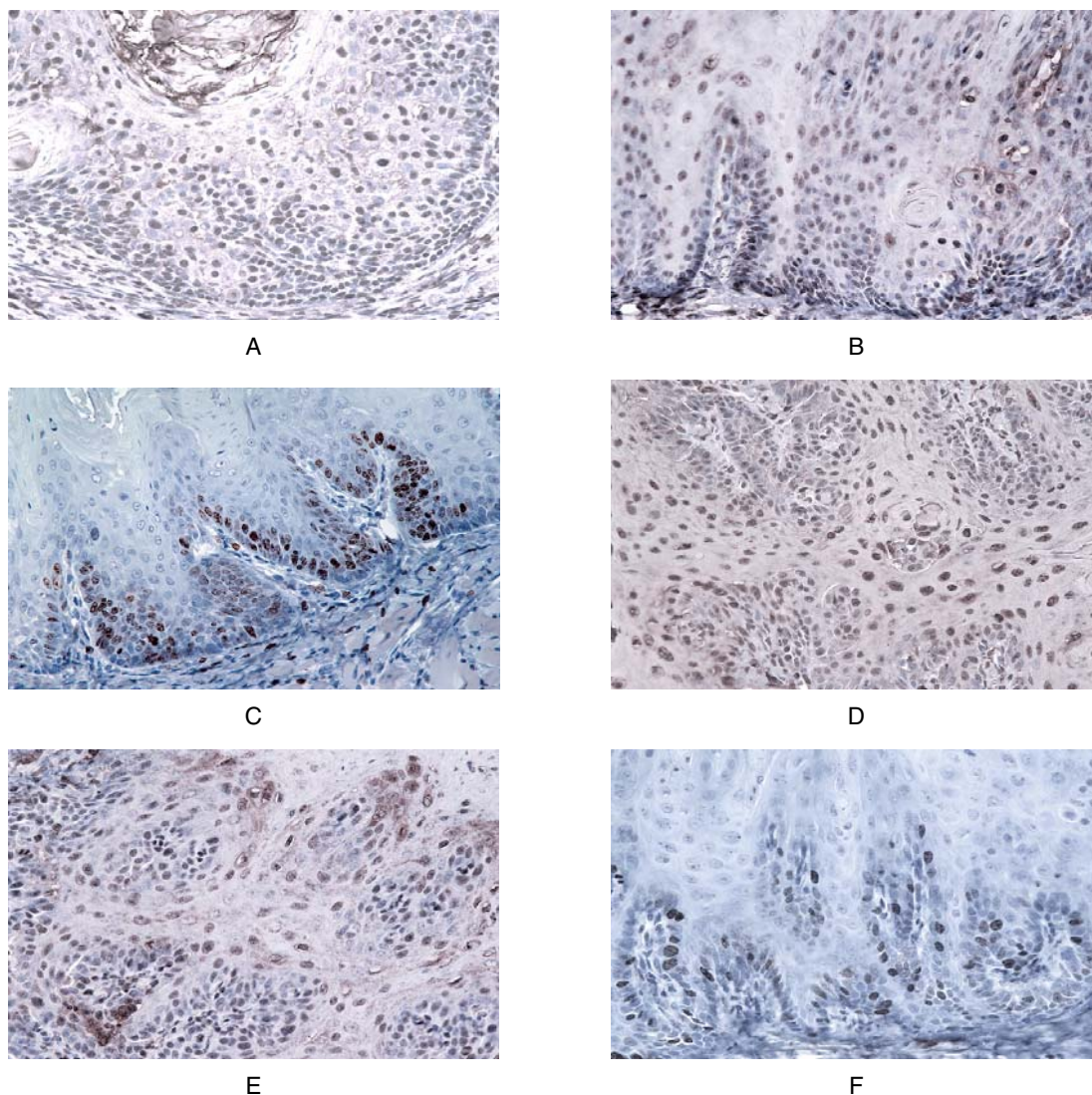




**Fig. 5** Labeling indices of phospho-NF- $\kappa$ B p65 in each experimental group.

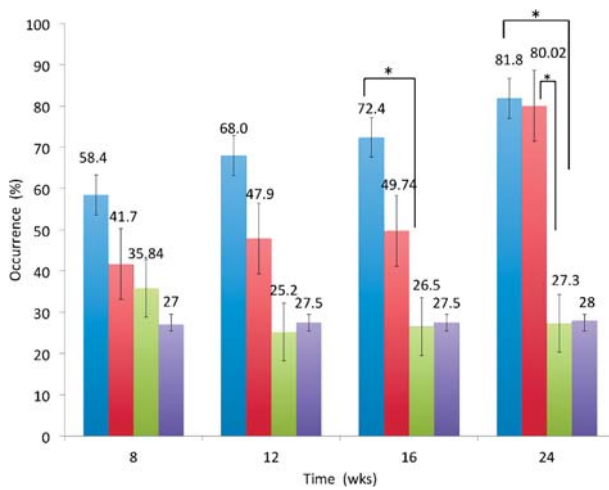
### **Proportion of phospho-NF- $\kappa$ B p65-positive cells**

The number of positive cells increased rapidly from week 8 in Group A and from week 16 in Group B, and increased further with malignant transformation. In Group C, expression levels similar to those in Group B were evident until week 12, but after this they declined to levels equivalent to those of the control group. The percentage of positive cells in Group C was obviously less than that in Group A, and this difference was significant ( $p < 0.05$ ) (Fig. 5).



**Fig. 6** Immunohistochemical staining of IKK $\alpha$ .

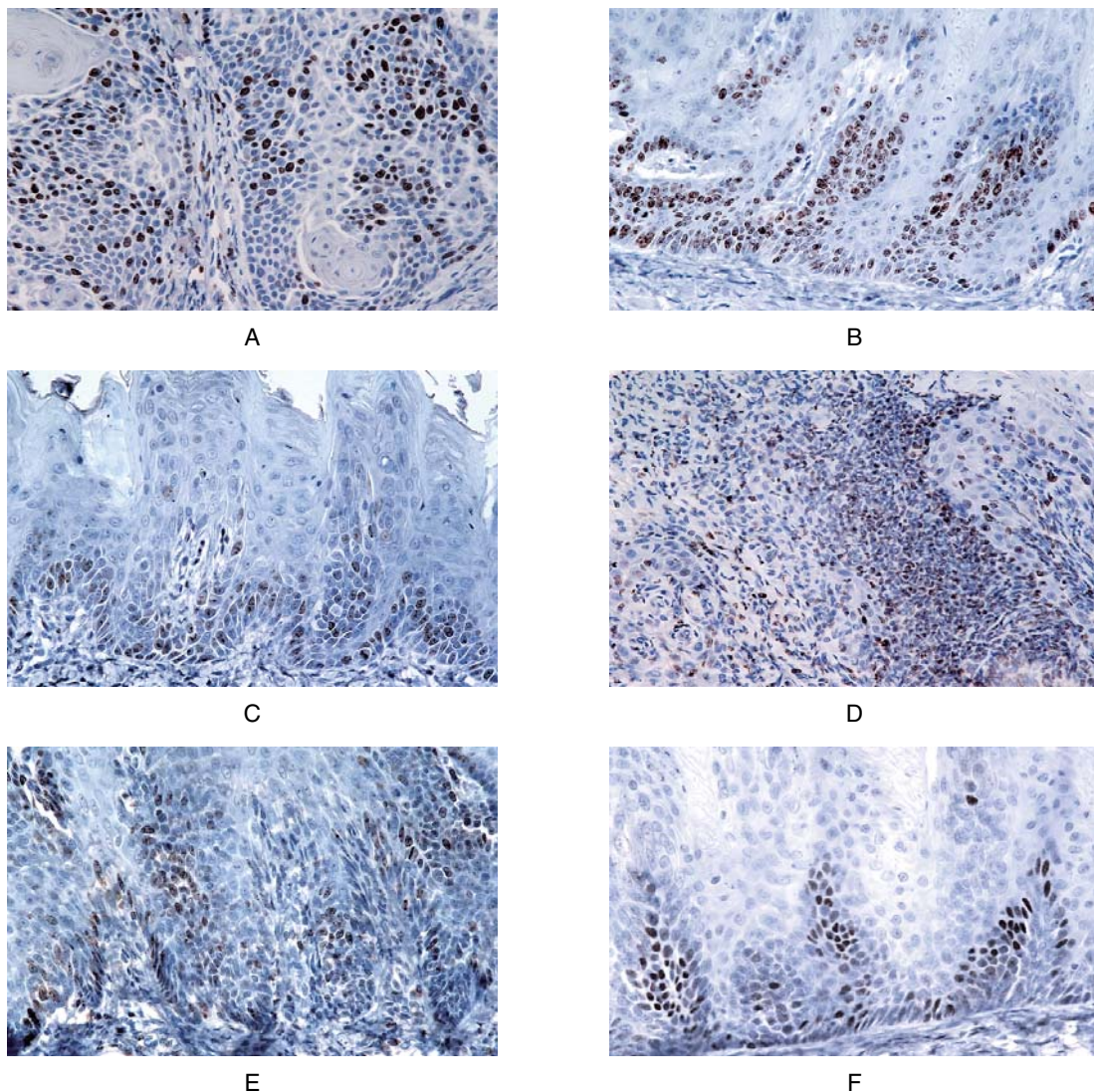
A: Group A at 16 wks, B: Group B at 16 wks, C: Group C at 16 wks, D: Group A at 24 wks, E: Group B at 24 wks, F: Group C at 24 wks ( $\times 100$ ).



**Fig. 7** Labeling indices of IKK $\alpha$  in each experimental group.

### **Localization of IKK $\alpha$ -positive cells**

IKK $\alpha$  immunostaining revealed predominant expression in the nuclei. In the control group, only nuclei in the stratum basal and the stratum parabasal were positive. In Groups A and B, at week 12 after 4NQO administration, positive cells had spread to part of the stratum spinosum, and by week 16 they had extended throughout the entire stratum spinosum. By week 24 there was strong expression within the nuclei of cells at the margin of the cancer foci. In Group C, expression was localized to the stratum basal, and although at week 16 it had spread to the lower third of the stratum spinosum, it remained localized.



**Fig. 8** Immunohistochemical staining of Ki-67.

A: Group A at 16 wks, B: Group B at 16 wks, C: Group C at 16 wks, D: Group A at 24 wks, E: Group B at 24 wks, F: Group C at 24 wks ( $\times 100$ ).



tum spinosum, there was no further spread of positive cells until week 24 (Fig. 6).

### Proportion of IKK $\alpha$ -positive cells

In Group A, the proportion was higher than in the control group from immediately after the start of 4NQO administration, and increased further with malignant transformation. In Group B it gradually increased, until by week 24 the level of expression was similar to that in Group A. In Group C, there was little difference from the control group, and the proportion of positive cells was significantly less than those of Groups A and B at both weeks 16 and 24 ( $p < 0.05$ ) (Fig. 7).

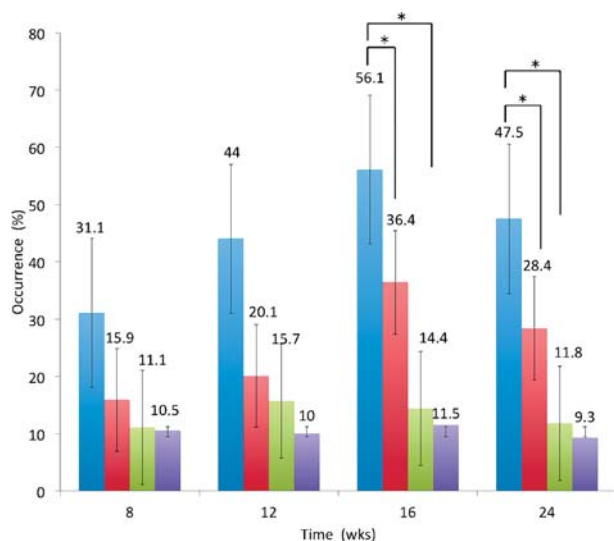


Fig. 9 Labeling indices of Ki-67 in each experimental group.

### Immunohistochemical findings for Ki-67 protein

#### Localization of Ki-67-positive cells

Immunostaining for Ki-67 revealed nuclear localization. In the control group, positive cells were evident in the stratum basal and the stratum parabasal. In Groups A and B, positive cells were also seen somewhat above the stratum parabasal. Positive cells increased at weeks 12 and 16, and by week 16 they were evident as far as the lower third of the epithelial layer. In weeks 20 and 24, positive cells had attenuated compared with week 16, and basal-cell-like positive cells were apparent at the tumor foci. In Group C, positive cells were almost entirely localized to the stratum parabasal (Fig. 8).

#### Proportion of Ki-67-positive cells

In Groups A and B, the number of Ki-67-positive cells decreased after week 16, and although in Group C they had increased somewhat at week 12, they subsequently decreased. At weeks 16 and 24, the proportions of positive cells decreased in both Groups B and C, and were significantly lower compared with Group A ( $p < 0.05$ ) (Fig. 9).

### SDS-PAGE and western blotting

Although phospho-NF- $\kappa$ B p65 was not apparent in the control group, a clear band was detected in Group A at 65-kDa at weeks 12 and 16, and strong expression was evident at week 24. Although the p65 band had attenuated in Group B at week 12, it was detected as

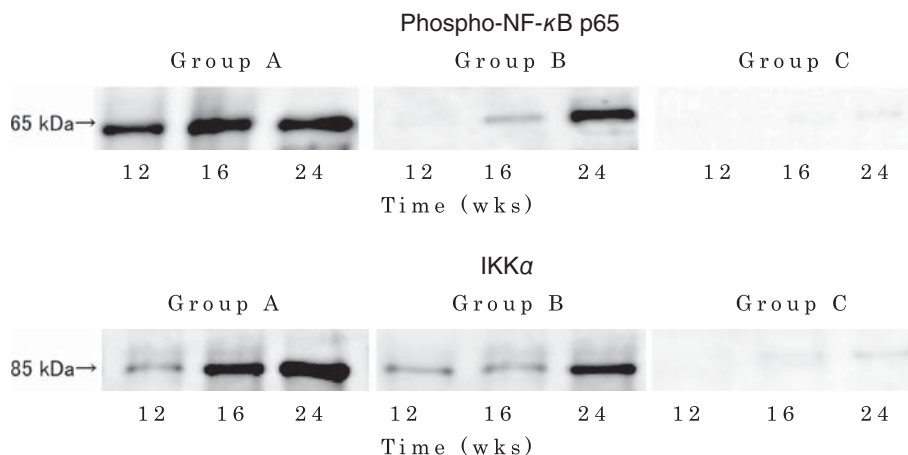


Fig. 10 Western blot analysis of phospho-NF- $\kappa$ B p65 and IKK $\alpha$ .



a clear band at 65-kDa at week 16. No clear band was evident in Group C. IKK $\alpha$  was detected in Group A as a band at 85-kDa. In Group B, a faint band was evident at weeks 12 and 16, and strong expression was evident at week 24. In Group C, a faint band was detected at 85-kDa at week 24 (Fig. 10). The control group tested negative for immunoreactions.

## DISCUSSION

We investigated the modifying effect of EGCG, the major component of green tea catechins, on 4NQO-induced tongue carcinogenesis in rats, and found that EGCG effectively suppresses carcinogenesis. Activation of NF- $\kappa$ B p65 was associated with this carcinogenesis-inhibiting effect in rats with tongue cancer induced by 4NQO.

In human head and neck squamous cell carcinoma, loss of the IKK $\alpha$  gene causes overexpression of activated NF- $\kappa$ B p65, which is reportedly involved with the malignant transformation of cells and infiltration and metastasis of squamous cell carcinoma.<sup>1</sup> Our results in this study suggest that in rats given 4NQO alone, the expression of IKK $\alpha$  and activated NF- $\kappa$ B p65 increases with malignant transformation, and that NF- $\kappa$ B p65 is involved in 4NQO-induced multi-step carcinogenesis. In rats given EGCG (Group B), the expression of IKK $\alpha$  and activated NF- $\kappa$ B p65 increased markedly from week 16, and as this was associated with the appearance of epithelial dysplasia and squamous cell carcinoma, it is highly probable that activated NF- $\kappa$ B p65 is involved in the malignant transformation of cells. In rats administered long-duration EGCG (Group C), the proportion of IKK $\alpha$ -positive cells was little different from that in the controls after 8 weeks, suggesting that the inhibition of IKK $\alpha$  decreased the proportion of activated NF- $\kappa$ B p65-positive cells, preventing the appearance of severe epithelial dysplasia and squamous cell carcinoma.

### EGCG activity in suppressing the promotion of carcinogenesis

EGCG not only inhibits the proliferation of human oral squamous cell carcinoma cell lines,<sup>2</sup> but has also been reported to remove activated oxygen,<sup>3</sup> exert an

antimutagenic effect,<sup>4</sup> induce apoptosis,<sup>5</sup> inhibit tumor angiogenesis,<sup>6</sup> and prevent tumor metastasis.<sup>7</sup> The carcinogenesis-inhibiting activity of EGCG is tumor-specific,<sup>8</sup> and has been demonstrated in numerous animal models of skin, esophageal, and gastric cancer.<sup>9</sup> This activity has been reported to be due to the trapping of active oxygen species by eight hydroxyl groups and a gallate group, preventing DNA damage.<sup>10</sup> Fujiki *et al.*<sup>11</sup> also reported that EGCG has a sealing effect that closes off cellular receptors so that they are unable to bind to carcinogenesis promoters, in addition to inhibiting the gene expression of TNF- $\alpha$  and other cytokines to suppress the promotion of carcinogenesis. This activity in suppressing the promotion of carcinogenesis has also been shown to be effective in mouse skin cancer two-step carcinogenesis experiments.<sup>12</sup>

Although in this study we found that administration of EGCG reduced the incidence of epithelial hyperplasia and epithelial dysplasia, it made no great difference to the incidence of lesions during the initiation period. During the promotion period, however, the occurrence of epithelial dysplasia and squamous cell carcinoma clearly decreased, suggesting that EGCG was exerting its action to suppress the promotion of carcinogenesis. Although numerous such anti-cancer promoters have been discovered, many are of high toxicity, and are therefore difficult to use clinically as carcinogenesis-preventing agents.

Polyphenol compounds, however, which are abundant in plants, are not cytotoxic, and green tea in particular contains large amounts of green tea catechins, meaning that drinking it may potentially be effective.

### Dynamics of activated NF- $\kappa$ B p65 and action in suppressing the promotion of carcinogenesis

NF- $\kappa$ B is the general name for a class of transcription factors first identified in 1986 by Sen and Baltimore<sup>13</sup> as factors that bind to the immunoglobulin- $\kappa$  short-chain enhancer region, and one of these, Rel A (p65), is present in cytoplasm in its inactivated state. Inactive NF- $\kappa$ B p65 is activated by phosphorylation by IKK $\alpha$  and immediately migrates inside the nucleus, where it functions as a carcinogenesis promoter. In a

study using JB 6 cultured cells derived from healthy mouse epithelial cells, EGCG was shown to be an important regulatory factor that suppresses the activation of NF- $\kappa$ B p65, inhibiting NF- $\kappa$ B sequence-specific DNA binding activity, and is therefore an important factor regulating the promotion of carcinogenesis.<sup>14</sup>

In our study, activated NF- $\kappa$ B p65 expression decreased in rats given EGCG compared with those administered 4NQO alone. The development of epithelial dysplasia and squamous cell carcinoma also increased in rats administered EGCG in association with increased expression of NF- $\kappa$ B p65. However, there was no increase in NF- $\kappa$ B p65 in rats administered EGCG for a longer period, and there was no occurrence of epithelial dysplasia or squamous cell carcinoma during the promotion period. Long-term administration of EGCG thus reduced activated NF- $\kappa$ B p65, significantly suppressing the promotion of carcinogenesis.

### **Dynamics of IKK $\alpha$**

Mutations in the IKK $\alpha$  gene have been shown to contribute to cell proliferation and malignant transformation, and this protein is reportedly overexpressed in human lung cancer and head and neck cancer.<sup>15,16</sup> In this study, we found that IKK $\alpha$  expression exhibited a similar tendency to increase in rats given EGCG as in those given 4NQO alone, but that its expression gradually reduced with long-term administration of EGCG. Although activated NF- $\kappa$ B p65 expression gradually increased in rats given EGCG, it decreased from week 12 in the group given long-term EGCG. This suggests a correlation between activated NF- $\kappa$ B p65 and IKK $\alpha$  expression. The suppression of the development of epithelial dysplasia and squamous cell carcinoma in rats given long-term EGCG may have been because the decrease in IKK $\alpha$  expression markedly suppressed the expression of activated NF- $\kappa$ B p65, enhancing its action in suppressing the promotion of carcinogenesis.

### **Cell proliferation activity**

Cell proliferation activity is a marker for detecting the promotion of carcinogenesis, and most substances that are chemopreventive against oral cancer are

known to act to suppress cell proliferation activity in the target organ.<sup>17</sup> The mechanism of carcinogenesis via epithelial hyperplasia and epithelial dysplasia seen in our experimental model is believed to be caused by mutations in tumor-suppressing genes or oncogenes.<sup>18</sup> Administration of 4NQO causes abnormal signaling during the epithelial dysplasia phase, meaning that the cell cycle becomes over-active and cell proliferation is activated in the entire stratum spinosum, resulting in multi-step carcinogenesis.<sup>19</sup> Studies using cultured cancer cells from a range of different human organs have also shown that activated NF- $\kappa$ B p65 down-regulates cyclin D and other cell-cycle-associated proteins as well as the cell cycle itself, contributing to malignant transformation.<sup>20</sup>

In this study, we did not find a significant difference between the labeling indices for activated NF- $\kappa$ B p65 and Ki-67. However, it is highly probable that decreased expression of activated NF- $\kappa$ B p65 suppressed cell proliferation activity. Long-term administration of EGCG also significantly decreased the proportion of Ki-67-positive cells, suppressing the development of moderate or severe epithelial dysplasia and squamous cell carcinoma. This suggests that EGCG inhibits cell proliferation activity of the lingual epithelium, suppressing progression to lesions with greater proliferation activity and malignant transformation.

Our study thus showed that the carcinogenesis-suppressing activity of EGCG was effective against rat tongue carcinoma induced by 4NQO. This carcinogenesis-suppressing activity may be exerted by decreasing activated NF- $\kappa$ B p65 expression, thus suppressing the promotion of carcinogenesis. We also showed that long-term administration of EGCG also decreased IKK $\alpha$  expression, enhancing its action in suppressing the promotion of carcinogenesis. EGCG administration did not prevent weight gain, and no histopathologic changes suggesting toxicity were evident in any of the major organs. As long-term oral administration would be preferable if it were to be used as a chemopreventive substance against cancer in humans, these findings are important.

In this study, EGCG administration increased the incidence of epithelial hyperplasia. Owing to en-

hanced cell proliferation activity, epithelial hyperplasia contains numerous cells in the mitotic phase that are easily targeted by carcinogens. Long-term administration of EGCG decreases IKK $\alpha$  expression, however, not only suppressing the promotion of carcinogenesis, but also reducing cell proliferation activity and effectively inhibiting multi-step carcinogenesis. EGCG may thus offer the potential for use as a chemopreventive substance against human tongue cancer, and may be useful for patients at high risk of this type of cancer. No other food ingredient exhibits such multifaceted carcinogenesis-suppressing activity, giving it many advantages for clinical use. Future studies are needed to elucidate the detailed action of EGCG in suppressing the promotion of carcinogenesis. As well, investigations into the activation mechanisms of IKK $\alpha$  and NF- $\kappa$ B p65 are important.

This study was funded in part by the 2012 Osaka Dental University Research Funds (Research theme No.12-09).

## REFERENCES

- Pontes HA, Pontes FS, Fonseca FP, de Carvalho PL, Pereira EM, de Abreu MC, de Freitas Silva BS, dos Santos Pinto D Jr. Nuclear factor  $\kappa$ B and cyclooxygenase-2 immunoexpression in oral dysplasia and oral squamous cell carcinoma. *Ann Diagn Pathol* 2013 ; **17** : 45–50.
- Paschka AG, Butler R, Young CY. Induction of apoptosis in prostate cancer cell lines by the green tea component, (–)-epigallocatechin-3-gallate. *Cancer Lett* 1998 ; **130** : 1–7.
- Khan S G, Katiyar S K, Agarwal R, Mukhtar H. Enhancement of antioxidant and phase II enzymes by oral feeding of green tea polyphenols in drinking water to SKH-1 hairless mice : possible role in cancer chemoprevention. *Cancer Res* 1992 ; **52** : 4050–4052.
- Okuda T, Mori K, Hayatsu H. Inhibitory effect of tannins on direct-acting mutagens. *Chem Pharm Bull* 1984 ; **32** : 3755–3758.
- Yang GY, Lio J, Kim K, Yurkow EJ, Yang CS. Inhibition of growth and induction of apoptosis in human cancer cell lines by tea polyphenols. *Carcinogenesis* 1998 ; **19** : 611–616.
- Cao Y, Cao R. Angiogenesis inhibited by drinking tea. *Nature* 1999 ; **398** : 381.
- Fujita S, Suzuki H, Kinoshita M, Hirohashi S. Inhibition of cell attachment, invasion and metastasis of human carcinoma cells by anti-integrin beta 1 submit antibody. *Jpn J Cancer Res* 1992 ; **83** : 1317–1326.
- Sadozuka Y, Sugiyama T, Hirota S. Modulation of cancer chemotherapy by green tea. *Clin Cancer Res* 1998 ; **4** : 153–156.
- Yang GY, Lio J, Kim K, Yurkow EJ, Yang CS. Inhibition of growth and induction of apoptosis in human cancer cell lines by tea polyphenols. *Carcinogenesis* 1998 ; **19** : 611–616.
- Fujiki H, Suganuma M, Okabe S, Sueoka E, Suga K, Imai K, Nakachi K, Kimura S. Mechanistic findings of green tea as cancer prevention for humans. *Proc Soc Exp Biol Med* 1999 ; **220** : 225–228.
- Komori A, Yatsunami J, Okabe S, Abe S, Hara K, Suganuma M, Kim SJ, Fujiki H. Anticarcinogenic activity of green tea polyphenols. *Jpn J Clin Oncol* 1993 ; **23** : 186–190.
- Yoshizawa S, Horiuchi T, Fujiki H, Yoshida T, Okuda T, Sugimura T. Antitumor promoting of (–)-epigallocatechin gallate, the main constituent of 'tannin' in green tea. *Phytotherapy Res* 1987 ; **1** : 44–47.
- Sen R, Baltimore D. Multiple nuclear factors interact with the immunoglobulin enhancer sequences. *Cell* 1986 ; **46** : 705–712.
- Nomura M, Dong Z. Inhibition of ultraviolet B-induced AP-1 activation by theaflavins from black tea. *Carcinogenesis* 2000 ; **28** : 148–155.
- Xiao Z, Jiang Q, Willette-Brown J, Xi S, Zhu F, Burkett S, Back T, Song NY, Datla M, Sun Z, Goldszmid R, Lin F, Cohoon T, Pike K, Wu X, Schrupp DS, Wong KK, Young HA, Trinchieri G, Wiltout RH, Hu Y. The pivotal role of IKK $\alpha$  in the development of spontaneous lung squamous cell carcinoma. *Cancer Cell* 2013 ; **23** : 527–540.
- Nakayama H, Ikebe T, Beppu M, Shirasuna K. High expression levels of nuclear factor  $\kappa$ B, I $\kappa$ B kinase alpha and Akt kinase in squamous cell carcinoma of the oral cavity. *Cancer* 2001 ; **92** : 3037–3044.
- Tanaka T, Mori H. Inhibition of colon carcinogenesis by non-nutritive constituents in foods. *J Toxicol Pathol* 1996 ; **9** : 139–149.
- Casson A G, Mukhopadhyay T, Cleary K R, Ro J Y, Levin B, Roth J A. p53 gene mutations in Barrett's epithelium and esophageal cancer. *Cancer Res* 1991 ; **51** : 4495–4499.
- Kadota H, Sakaki T, Kakudo K. Correlation between cell kinetics and P-cadherin expression in rat tongue carcinogenesis induced by 4-nitroquinoline 1-oxid. *Jpn J Oral Maxillofac Surg* 2001 ; **47** : 770–777. (Japanese)
- Su J, Zhao P, Kong L, Li X, Yan J, Zeng Y, Li Y. Trichothecin induced cell death in NF- $\kappa$ B constitutively activated human cancer cells via inhibition of IKK $\alpha$ . *Phosphorylation* 2013 ; **8** : 1–8.